

Milan 2005

“I wish I hadn’t done that!”

John Lee

Moorfields Eye Hospital

London

Ms T. M.

A pattern exotopia

Ms T.M.,
d.o.b. 13/11/57

- Intermittent exo noted from around 6 months. Seen by Kenneth Wybar 20/11/58. Initially observed.
- 31/7/63
 - LLR recession 7mm, LMR resection 3mm
- 7/8/68
 - RLR recession 7mm, RMR resection 5mm

Ms T.M.

- October 1968 – consecutive esotropia
- 27/11/68
 - RMR recession 5mm, RLR advanced to old insertion
- Recurrent exophoria and headaches – given exercises – later prisms
- 30/4/75
 - RMR advancement 4mm, RLR recession 5mm

Ms T.M.

- October 1978 – noted to have A exo pattern
- 13/12/78
 - Bilateral SO posterior tenotomies
- Post-op – still A pattern but subjectively better for some time. Given bifocals with +1.00 add and prisms - 6 Δ base in R & L
- *1983 – Kenneth Wybar retires*
- *1984 – I return from America*

Ms T.M.

- Seen by me in May 1984.
- Working as graphic designer. Near vision symptoms +++
- Large A exophoria
 - 18 Δ upgaze
 - 18 Δ primary position
 - 35 Δ downgaze
 - Downdrift each eye on adduction

Ms T.M.

- 27/6/84
 - Bilateral complete SO tenotomies (at nasal border of SR)
- Completely unable to open eyes post-op
- Discharged 29/6/84 with eyes still shut

Ms T.M.

- Two weeks later – first post-op clinic visit
- Bilateral superior oblique palsies
 - Excyclotorsion 15° R, 10° L
- *Very* distressed
- RVA blurred
 - axis of astigmatism changed from 10° to 80°
- *Discovered to have numerous medical and legal relatives. Most of them ring me.*

Ms T.M.

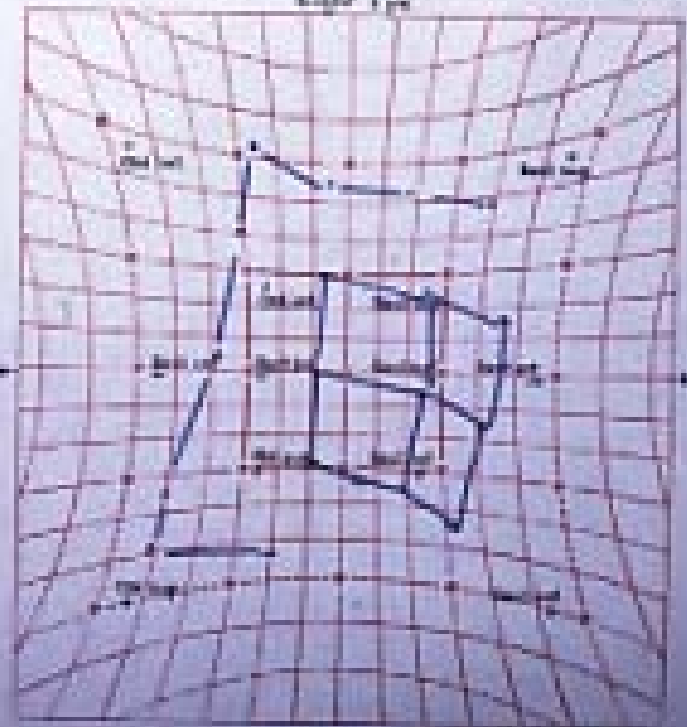
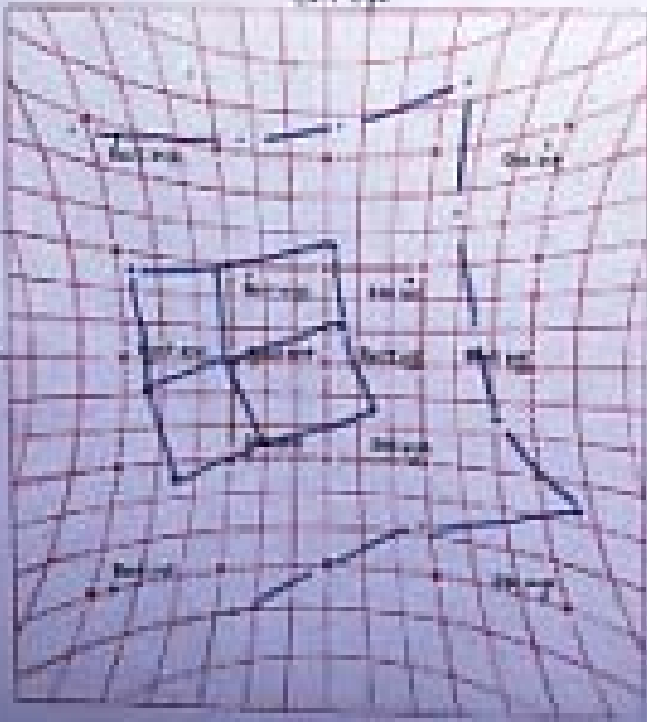
POST BILAT. S.O. TENOTOMIES
DIAGNOSIS

T.M. (S21663)

9-7-84

Left Eye

Right Eye



Green before left eye

Green before right eye

Ms T.M.

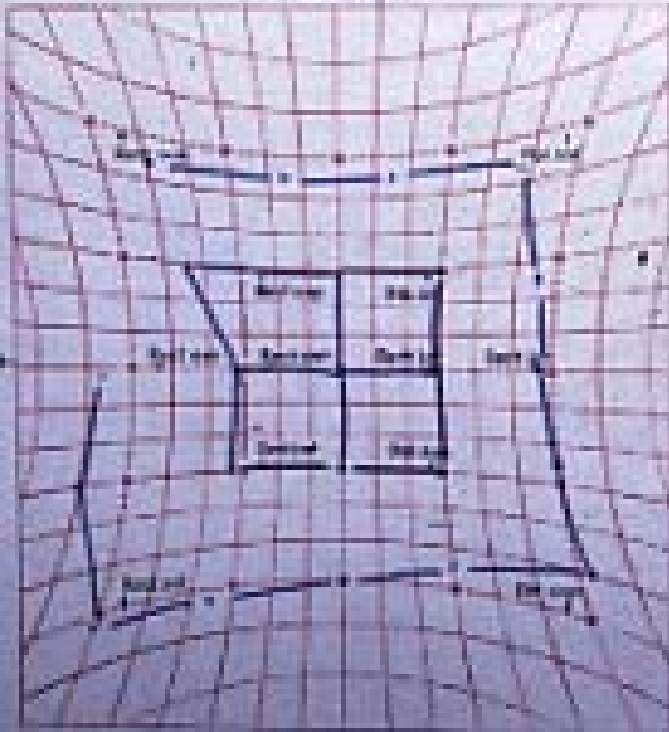
- Plan #1 – get a second opinion
 - Peter Fells and John Elston kindly say “these things happen”.
- Plan #2 – further surgery
- 19/9/84
 - LIO recession
- Post-op, subjectively better, still R hyperphoria with extorsion on downgaze
- Back to work

Ms T.M.

Post LIO
DIAGNOSIS

T.M. (S2166A)

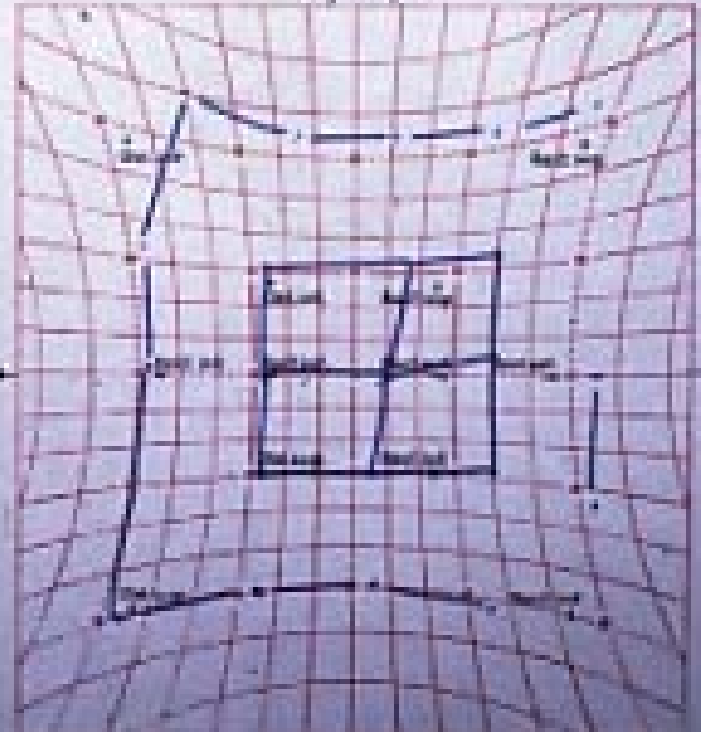
Left Eye



Cover before left eye

25 9 84

Right Eye



Cover before right eye

Ms T.M.

- 26/11/84
 - RIO recession
- Still extorsion on downgaze
- Exotropia with “X” pattern

Ms T.M.

POST R10
DIAGNOSIS

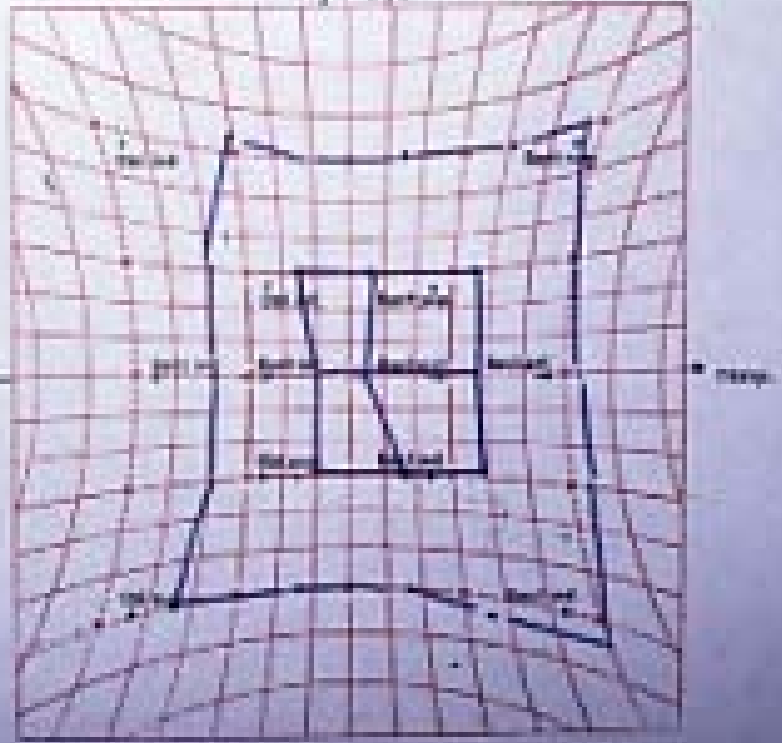
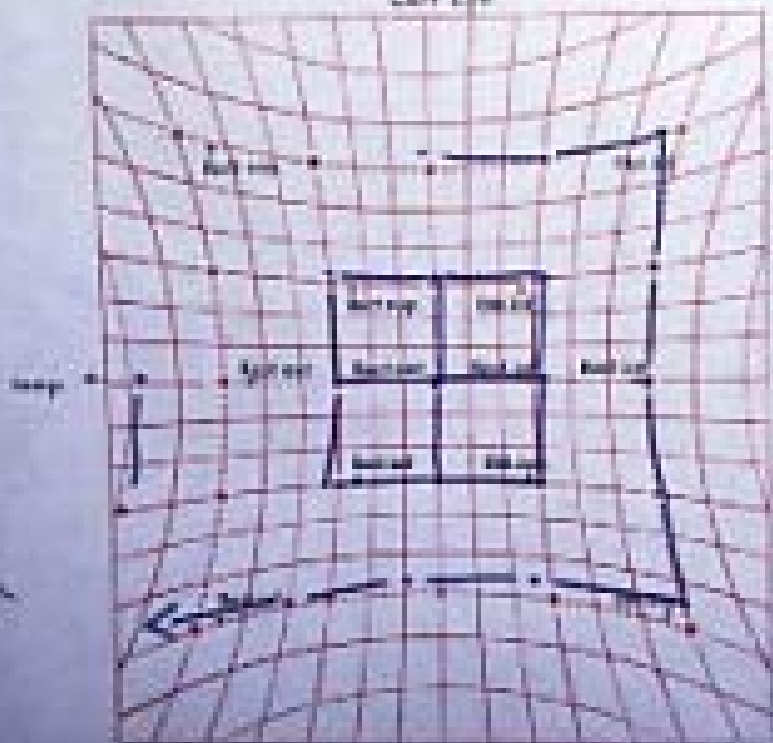
No. 11

T.M. (S21669)

4-12-96

Left Eye

Right Eye



Cross before left eye

Cross before right eye

Ms T.M.

- 27/3/85
 - Exploration and reattachment of both SO tendons. LLR found at 14mm from limbus. Scarred ++++. Attempted central tenotomy.
- Post-op better, i.e. similar to before my 4 operations
- Prisms reordered. Discharged 24/9/85

Ms T.M.

POST S.O. REATTACHMENT
DIAGNOSIS R+L

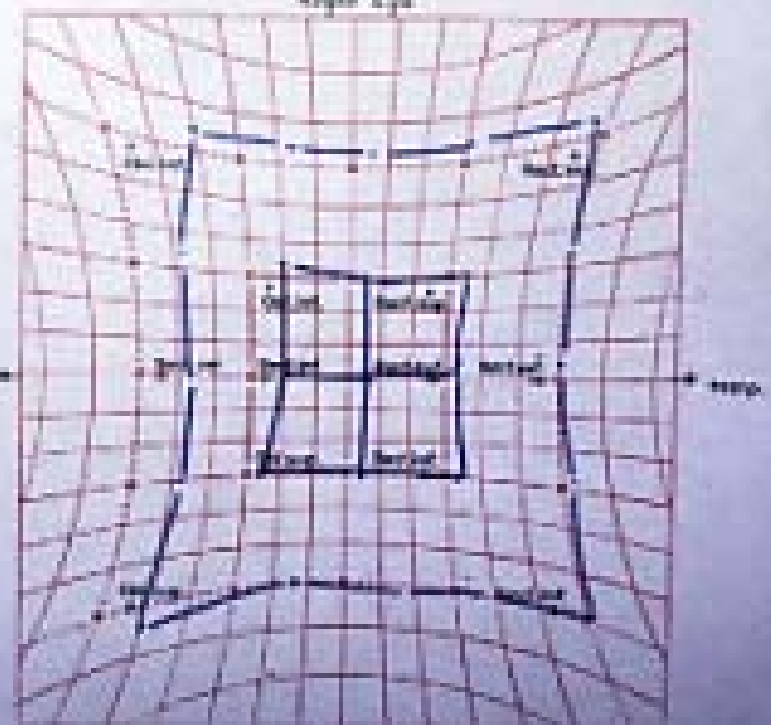
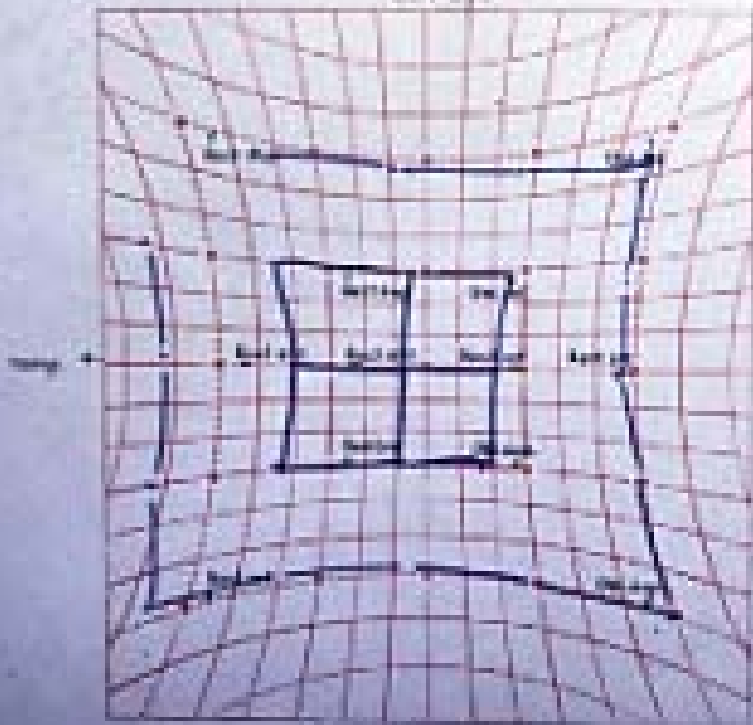
T.M. (521669)

30-3-85

No. 19

Left Eye

Right Eye



Green before left eye

Green before right eye

What did I learn?

- 1. The sixth operation is not more likely to be more successful than the preceding ones.
- 2. Don't completely divide the superior oblique tendons in a binocular patient.
- 3. When things go wrong, (or even sooner) seek the opinion of your colleagues.

Miss G.F.

Accommodative Esotropia

Miss G.F.

- First seen at 13 months
- Esotropia from 6 months
- On examination at that time “straight”
- Overcomes a prism
- Atropine refraction +6.00 R & L

Miss G.F.

- Age 2½ - now definite ET on accommodation
- Glasses given - +6.00 R & L

Miss G.F.

- Age 3½ - Rx +6.50 R & L
- Age 5½ - Rx + 7.50 R, +6.50 L
- Age 6½ - Rx +9.00R, +8.50/-2.00 x 30° L

Miss G.F.

- Seen by me 1982
- Wearing +8.50 R, +8.75/-2.00 x 55° L
- Very variable esotropia
 - Up to 45 Δ
 - AC/A ratio 15:1
- R amblyopia
- Not an easy child to manage
- Mother keen for surgical solution

Miss G.F.

- August 1982 – admitted for surgery
- John Lee to orthoptist: “It would be impossible to overcorrect this child.”

Miss G.F.

- 19.8.82
 - *Bilateral MR recession 5mm*
 - *Bilateral MR faden at 14mm*
- Post-op immediately exotropic near and distance

Miss G.F.

- Tried with reduced correction
 - +5.50 right
 - +5.00 left
- Still XT most of time – very variable

Miss G.F.

- January 1983
- I go to America

Miss G.F.

- Child wearing reduced correction at school
- Not doing well
- Still XT most of time – around 25Δ
- February 1983 – given full correction
- Better acuity

Miss G.F.

- 5.8.83 Surgery (John Elston)
 - *RLR recession 7mm*
 - *Dissection of faden and RMR advancement 5mm*
- Better cosmesis post-op

Miss G.F.

- Last examination 21.5.85
- With glasses 8ΔXT
- Without glasses 8ΔET
- Discharged

Miss G.F. – What did I learn?

- Increasing hypermetropia is a bad prognostic sign for binocular function potential
- Hypermetropic eyes are small eyes, so surgery can be over-effective
- You can't always save the day with a reduced hypermetropic correction

Miss G.F.

What would I do now?

- Wait and see
- ? Order glasses earlier in management
- No surgery
- Talk about contact lenses and consider prescribing them from around age 11

Master A.A.

Bilateral Duane's Syndrome

Master A.A.

- D.o.b. 6.9.98
- L esotropia from birth
- Tendency to elevate chin
- Referred by colleague
- First seen by me 16.8.99

Master A.A.

- Binocular VA ? 6/120
- Chin up AHP
- Marked limitation of abduction both eyes
- “A” ET pattern
- ? Some stereo on Frisby test
- Refraction +2.25 R, +2.00 L
- Glasses ordered

Master A.A.

- Seen again 15.12.99
- Not wearing glasses well
- Still chin up +++
- RVA 6/19, LVA 6/9 (Cardiff cards)

Master A.A.

- Continues to attend up to February 2002
- Vision equal
- Chin up still
- Stereo - Wirt fly positive
- Discussion about surgery

Master A.A.

- *5.3.02 Supraplacement of both medial recti one insertion width.*
- First post-op visit “no head posture seen”
- Small XT
- Limited adduction and abduction

Master A.A.

- Over next few visits, XT gets steadily bigger
- Vision equal
- No head posture
- No stereo

Master A.A.

- June 2003 – RXT 45 Δ and R hypertropia
- Limited adduction R > L
- Further surgery discussed

Master A.A.

- *9.12.03 – R LR recession 5mm, R MR found 10mm from limbus, advanced to 4mm.*

Master A.A.

- Seen 3 weeks later
- Mother says “Looked better for 2 weeks, now R eye drifting out again”
- R XT 40 Δ
- Eye movements the same as before

Master A.A.

- Most recent visit 9.8.05 – aged 6³/₄
- RVA 6/12, LVA 6/9
- Alternating XT of 45Δ
- Variable face turn
- Still grossly restricted adduction and abduction
- Discussion regarding more surgery

Master A.A.

What did I learn?

- Duane's are difficult
- If you induce a consecutive XT it is very difficult to retrieve the situation
- One can destroy binocular function in a child of 4 with well-intentioned surgery

I'm glad I didn't do that!

Mr M.J.

“Intractable” diplopia in a young man

A sad story

Mr M.J.

- Date of birth 22.6.66
- Anisometropic from childhood
- Left eye myopic
- Right eye hypermetropic and amblyopic
- Left occlusion as child
- Left radial keratotomy 1989
- Procedure on right eye on Russian hospital ship 1990

Mr M.J.

- Seen 8.3.95
- “Poor co-ordination of eyes. Has to consciously control eyes, otherwise diplopia”
- VA 6/9 R, 6/4 L. Minute L hypophoria
- Prism fusion range – 35 base out to 16 base in
- Stereo 120” on TNO

Mr M.J.

What to do?

- Occlusive contact lens suggested
- Fitted to R eye June 1995
- Initially successful, then further symptoms
 - R eye aches and feels heavy
- “Can’t work” – has worked 6 weeks in past 4 years!

Mr M.J.

- Letter from patient
- “I will be 30 years old in June. In the past 8+ years I have seen 6 consultants and a number of orthoptists. I have undergone eye exercises, press-on prisms, occlusion and surgery to correct refractive error in both eyes. I have been unemployed for over 5 years. In my current circumstances I would not enter into a serious relationship...because I know that so long as the frustrations of my present situation remain I will not be able to achieve either happiness or fulfilment”

Mr M.J.

- “ I am now convinced that in the absence of an alternative, the best chance I have of being able to lead a fulfilling life is with the removal of my right eye. I would, of course, be willing to sign any form required to make it clear that the proposed surgery was willingly undergone”

Mr M.J.

What to do now?

- Long discussion
- Request for enucleation refused
- Botulinum toxin ptosis offered
- Botulinum toxin to R levator x 2
- “No better, still aware of R eye”
- Reverts to occlusive lens. Discharged.

Mr M.J.

- Letter from psychiatrist May 1997
- “ I wondered if there were any circumstances under which you might consider such radical surgery, if I were to think it justified in Mr J’s case on psychiatric grounds (which I emphatically do not at the moment).”

Mr M.J.

- Could I have done anything else?

Mr M.J.

- November 2005
- Committed suicide

Thanks for your
attention.