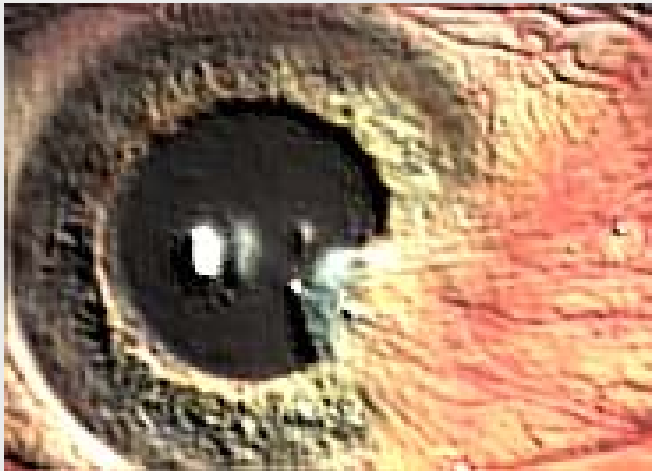

Chirurgia dello Pterigio



Maurizio Rolando

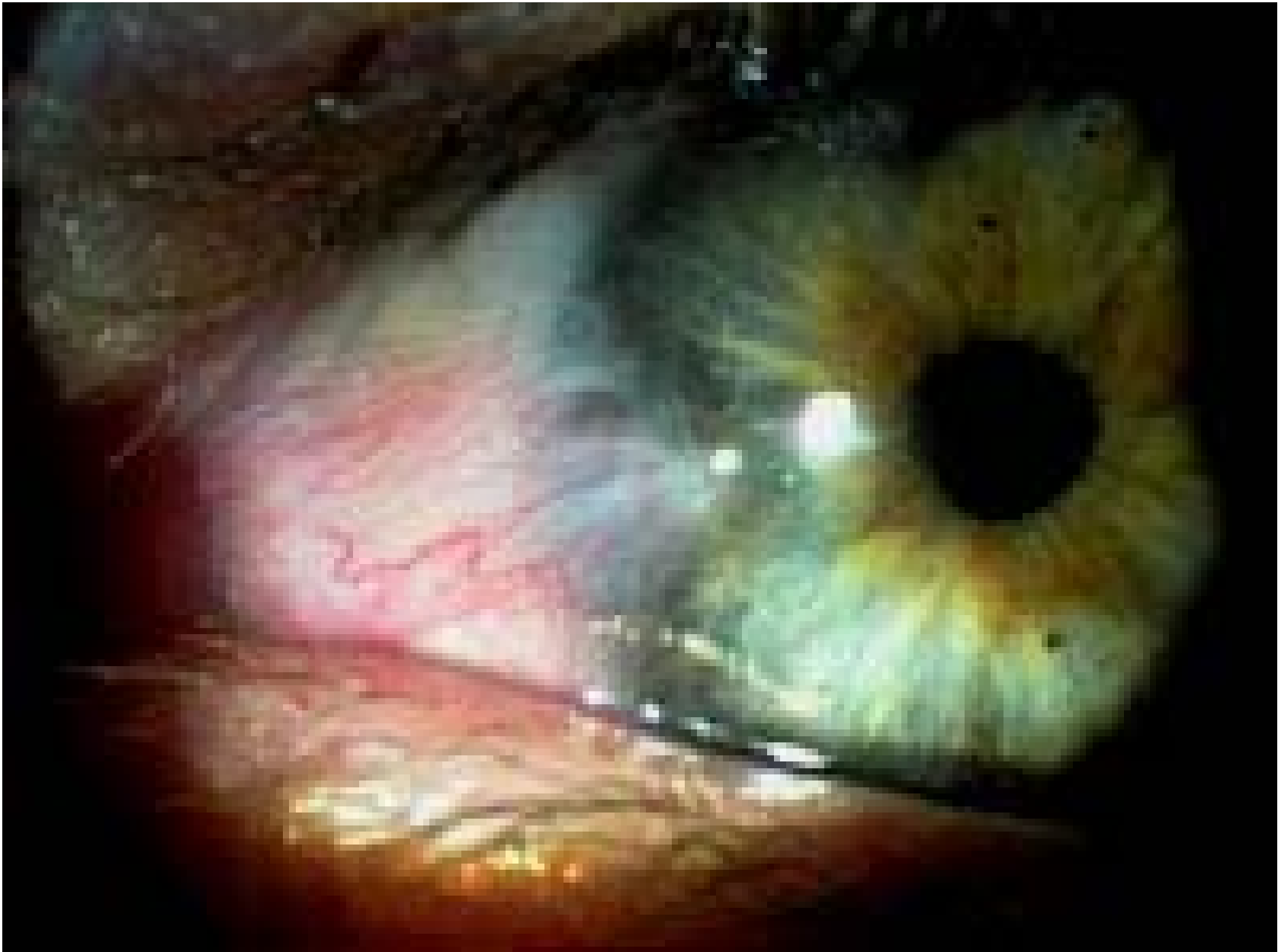Clinica Oculistica

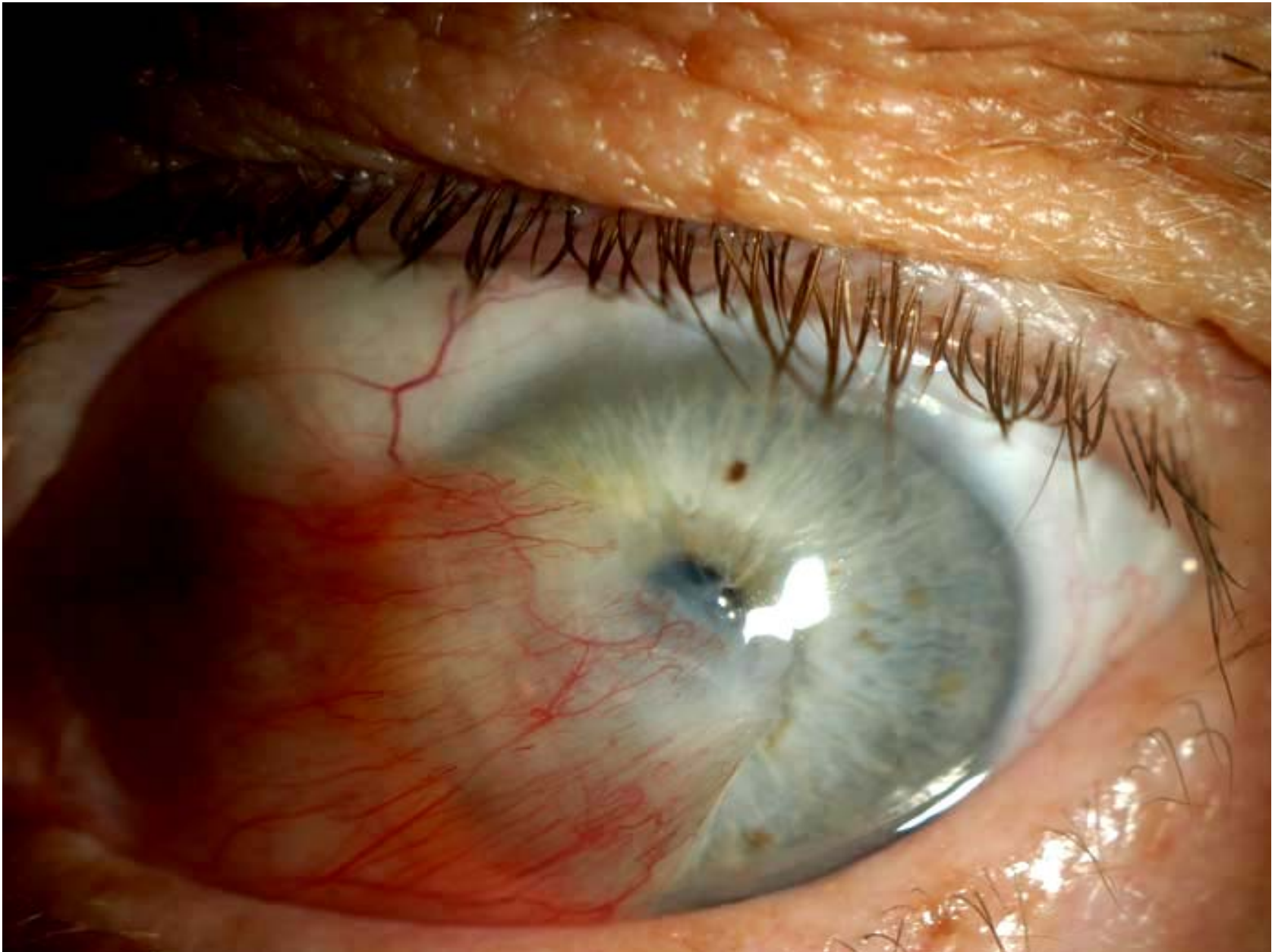
Dipartimento di
Neuroscienze, Oftalmologia
e Genetica

Università di Genova

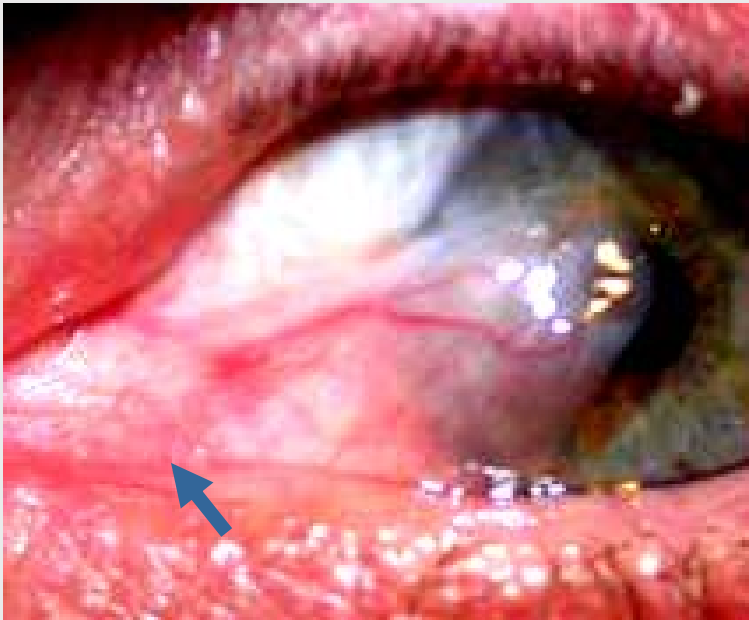Lo Pterigio è una delle malattie congiuntivali più difficili da gestire

- danno estetico
- disturbi visivi
- invasione del tessuto corneale
- infiammazione
- disturbi della motilità
- recidive

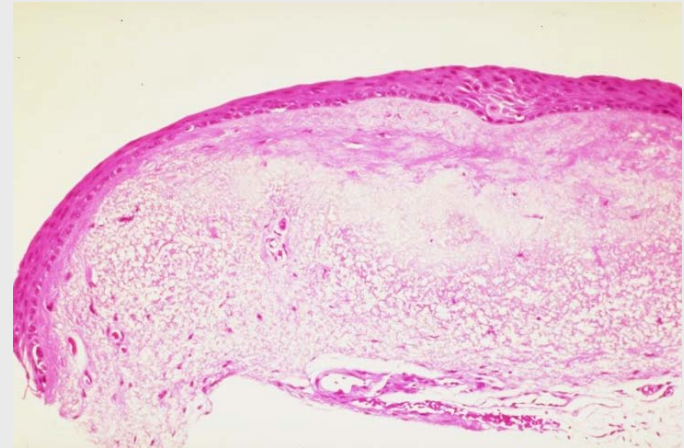




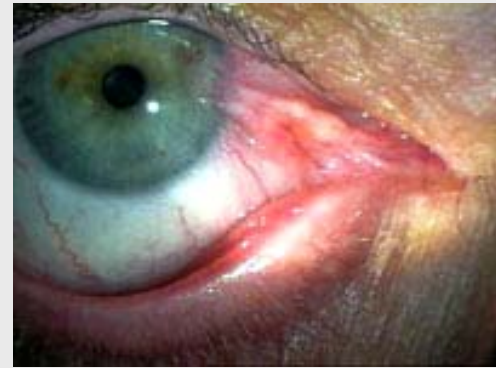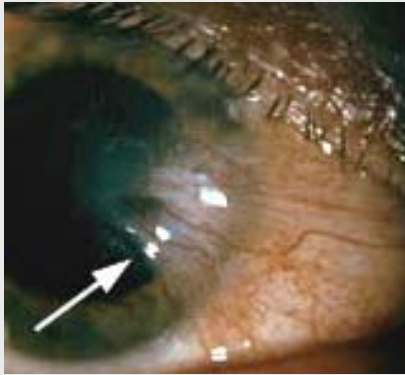Pterigio: considerazioni pre chirurgiche



- Lo pterigio non è solo proliferazione ma è soprattutto spostamento (trazioni) e infiammazione

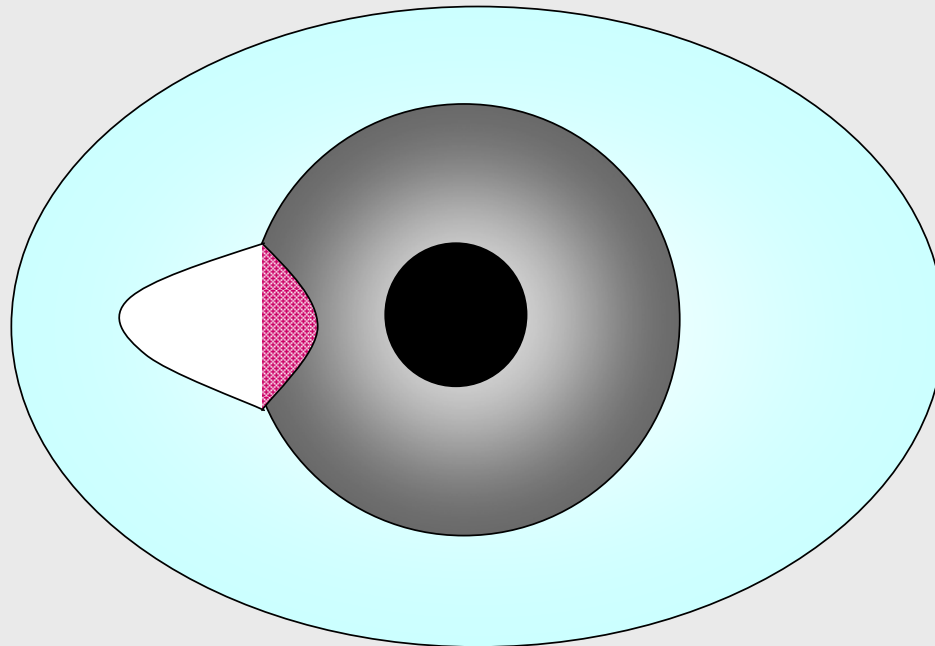


Chirurgia dello Pterigio: Evitare le sorgenti di Infiammazione



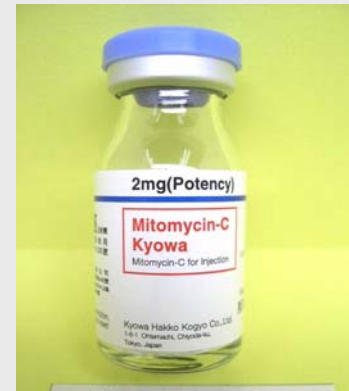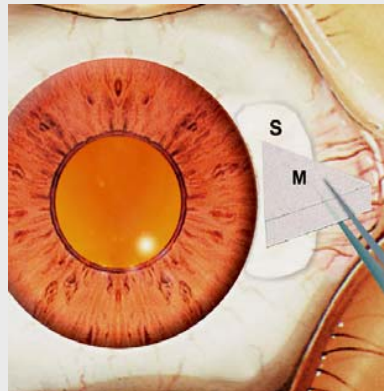
- Man mano che il tessuto migra verso la cornea vi è una trazione sulla piega semilunare.
- Molti chirurghi tendono ad asportare tutta la parte arrossata, danneggiando però la piega semilunare, con:
 - danno estetico
 - aumento l'infiammazione post op e il rischio di recidive
- Cercare di separare la porzione che prolifera da quella che si è mossa
- Rimuovere una minima quantità di tessuto
- Asportare il Tenone infiammato
- Sostituire il tessuto asportato con un lembo libero o con la membrana amniotica

Sclera Nuda



Applicazione di antimetaboliti per prevenire le recidive nella chirurgia dello pterigio

- Mitomicina C
- 5 Fluorouracile
- Danurobicina
- Doxorubicina



- Mitomycin - C, antimetabolita noto in oftalmologia
- Singola applicazione per 3 minuti di una spugna bagnata con 0,1 cc di 0,4 mg/ml (0,04%) sull'area esposta chirurgicamente
- Dopo il trattamento lavare la sclera

Intraoperative Mitomycin C 0.02% for Pterygium: Effect of Application on Recurrence Rate.

Avisar R, Gatton DD, Loya N, et al. Cornea 2003; 22(2):102-4

- After 12 months of follow-up, pterygium recurred in 20 patients (33.3 percent) in **No Mitomycin** Group and in 2 patients (2.7 percent) in **Mitomycin** Group.
- After 15 months, the recurrence rates were 36.6 percent and 5.4 percent, respectively, and remained unchanged at 26 months.
- Clinicians observed no cases of drug toxicity in either group.

Results of the ^{90}Sr - and ^{90}Y -radiation after surgical removal of 123 pterygia.

Payer, H.. Klin Monatsbl Augenheilkd. 1979, 174: 993-8

- 123 pterygia were surgically removed.
- After surgical removal of the pterygia followed a treatment with strontium 90 beta radiation with 2700 rep: 900 rep at the 2nd, 8th and 15th day after surgery.
- The recurrence rate was high (16%), but lower than it is reported in these groups operated without following radiation (62%).

Late complications of pterygium post op Beta-Irradiation treatment.

Tarr, K. H., Constable, I. J. Br J Ophthalmol 1980; 64: 496-505

- complications were assessed 3 to 20 years later (mean 12 +/- 3).
- The pterygia were excised, leaving bare sclera, and beta irradiation of total dose 750 to 5200 rads (mean 3475 +/- 916) was given.
 - **Scleral ulceration** was present in 51 eyes and sectorial lens opacities with normal visual acuity (VA) in 19 eyes.
 - Radiation induced **cataract** occurred in 3 eyes, with reduced vision.
 - **Ptosis, symblepharon, and iris atrophy** were also seen.
 - **Pseudomonas endophthalmitis** occurred in 4 patients with scleral ulceration.
- Beta irradiation to prevent recurrence of pterygia is a significant cause of iatrogenic ocular disease. **There is a need to modify the beta irradiation dosimetry at present in use.**

The Amniotic Membrane

- A stable, non moving, rich epithelium over a thick basement membrane

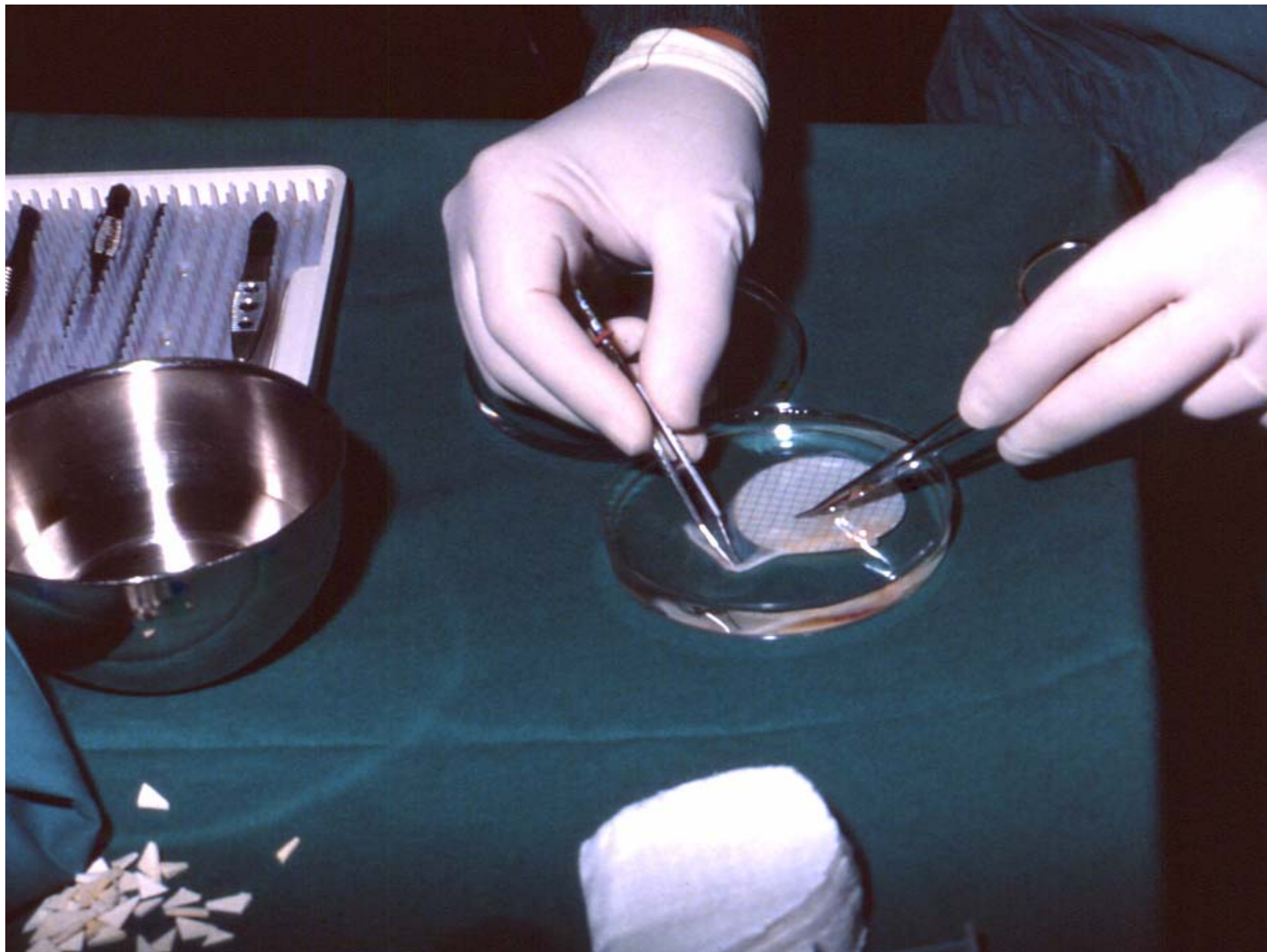Comparison of amniotic membrane graft alone or combined with intraoperative mitomycin C to prevent recurrence after excision of recurrent pterygia.

Ma, D. H., See, L. C Hwang, Y. S.Wang, S. F. Cornea 2005 24:141-50

- Regarding the recurrence rates of each group,
 - 6 conjunctival (12.5%) and 6 corneal (12.5%) recurrences developed in the AMG group,
 - and 4 conjunctival (8.5%) and 6 corneal (12.8%) recurrences developed in the AMG-mitomycin C group.
 - No significant difference was found in the conjunctival and corneal recurrence rate between the 2 groups ($P=0.623$ and 0.966 , respectively; log rank test), and no major complications developed in either group.
- **CONCLUSIONS: AMG alone can be considered an effective alternative adjunctive treatment of recurrent pterygia.** The addition of intraoperative mitomycin C did not further reduce the recurrence rate.


Transplanted A. M. :

- *Fresh* *(Addis Pj, BrJ Ophthalmol, 2001)*
- *Low-heat dehydrated* *(John OC, ARVO, 2002)*
- *Cross-linked* *(Petersen H, ARVO 2002)*
- *Cryo-Preserved (-80°C)* *(Tseng S, 1988)*



Pterygium

Amniotic membrane

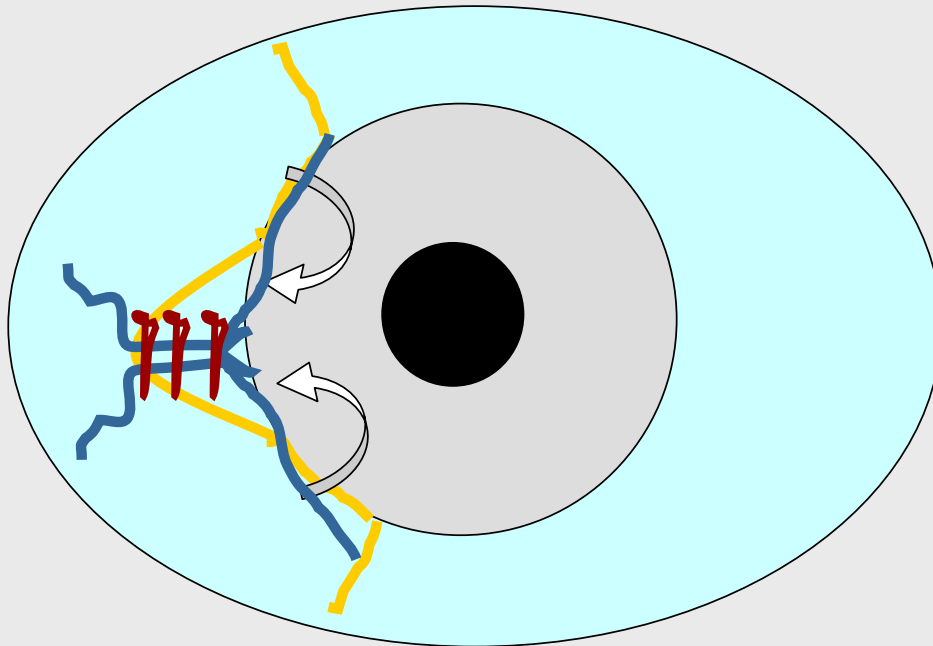


Trapianto di M.A. 1998-2003 (1)

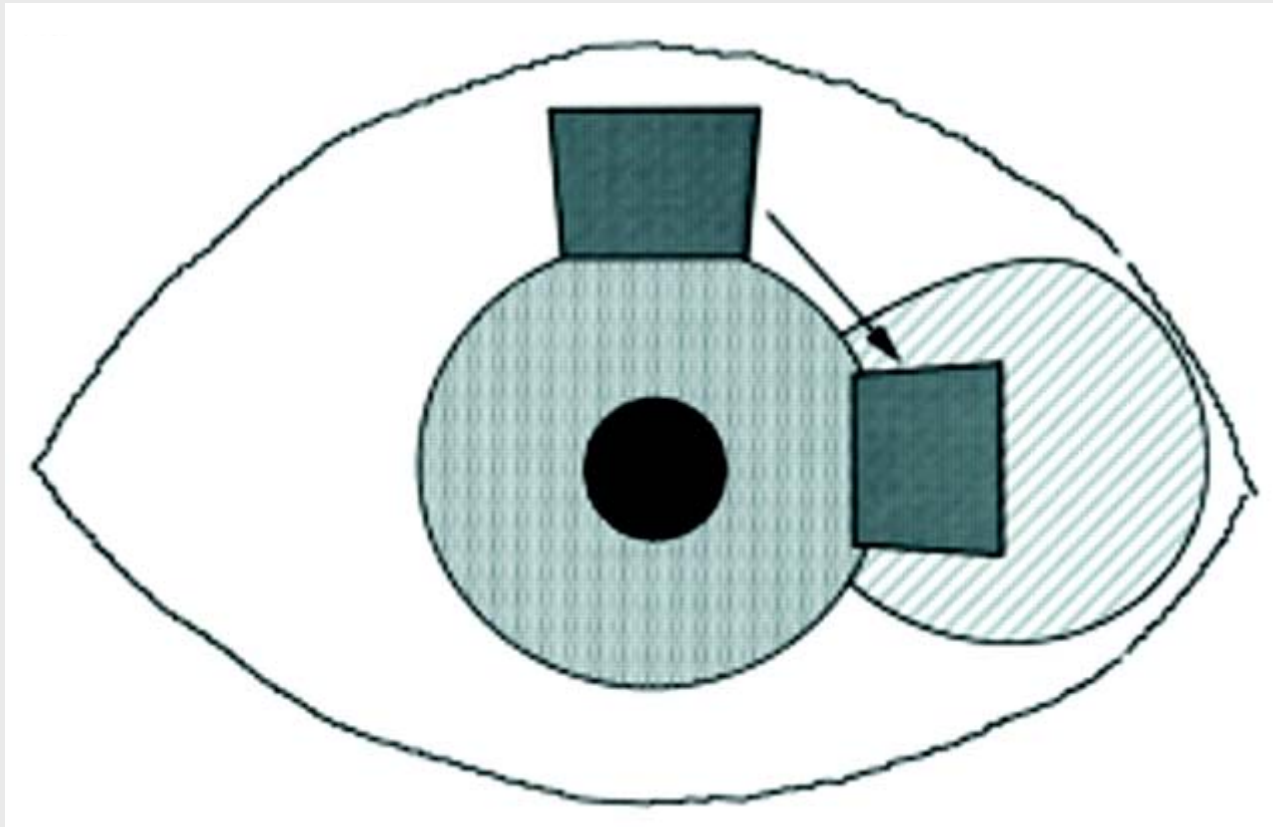
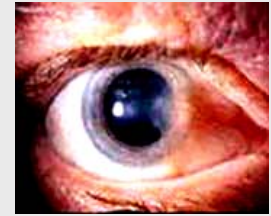PATOLOGIA	n. trattati	n. successi
pterigio	18	7
simblefaron	6	4
ricostruzione sup. oc. post ustione da alcali	10	4
ricostruzione sup. oc. post radiazioni	2	0
ricostruzione sup oc in pemfigoide	11	7*
neoformazione congiuntivale	4	4
congiuntivo calasi	7	7

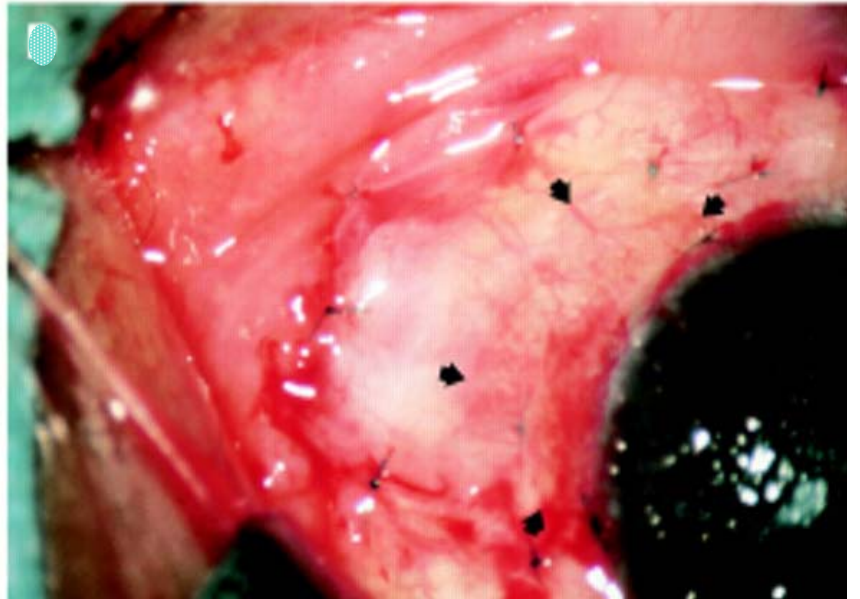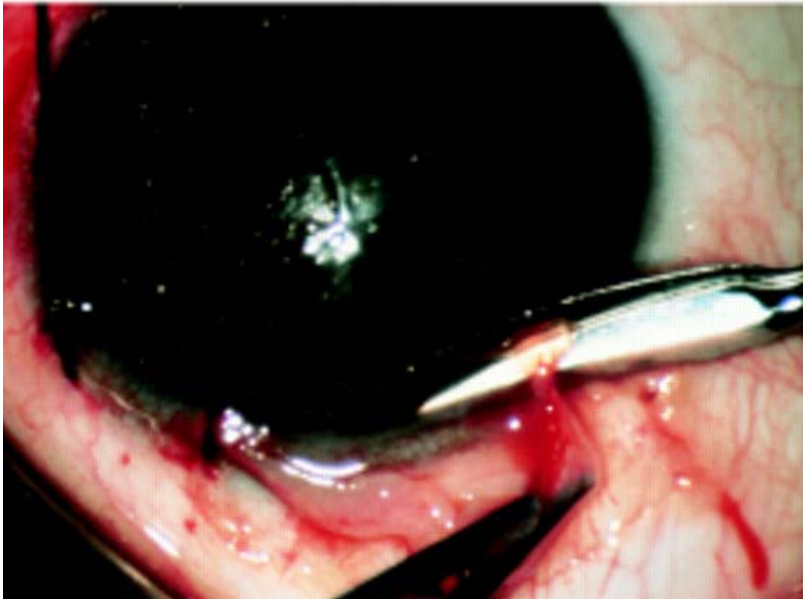
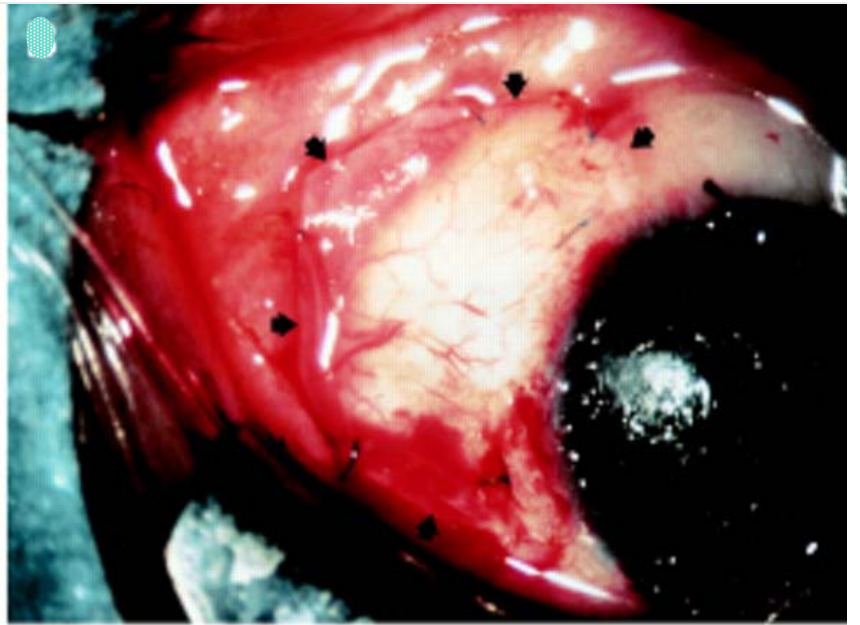
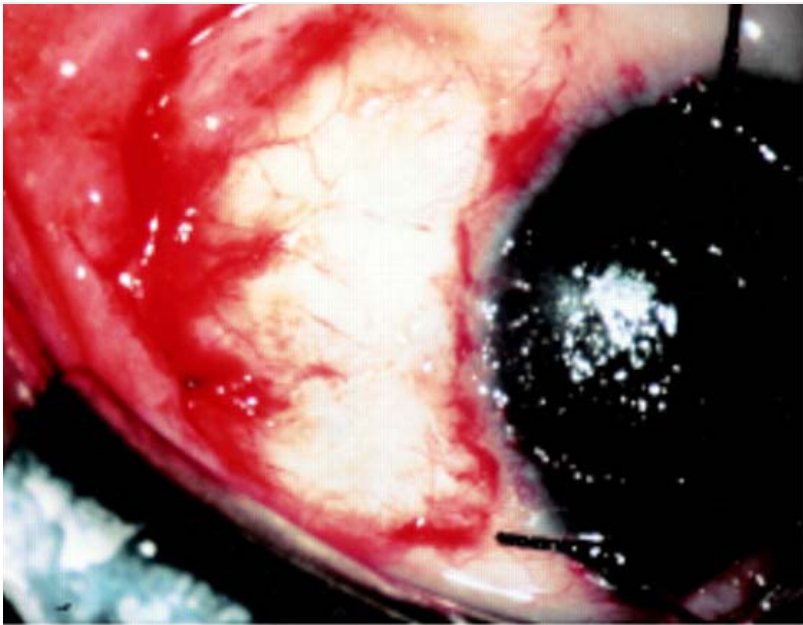
*Follow-up minimo 16 mesi

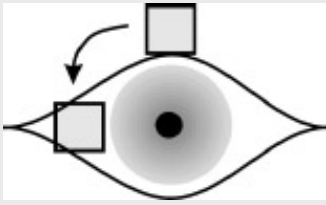
Plastica congiuntivale



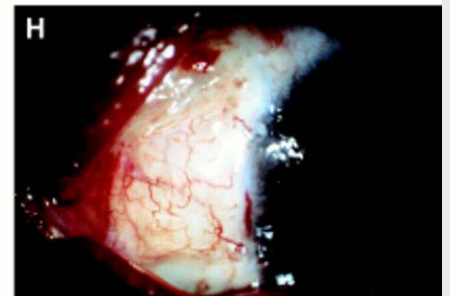
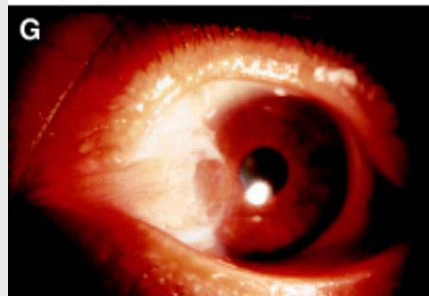
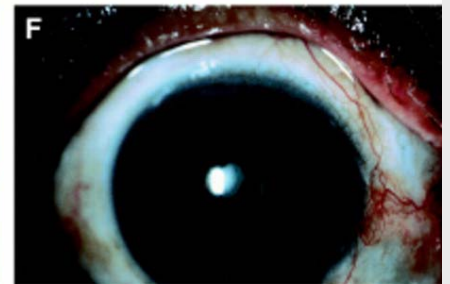
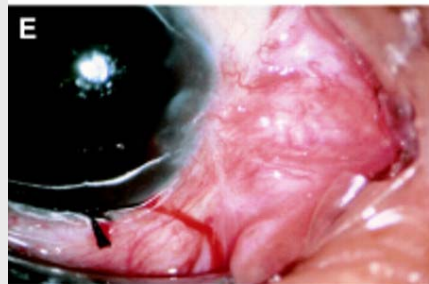
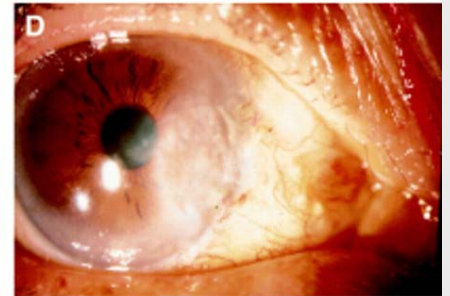
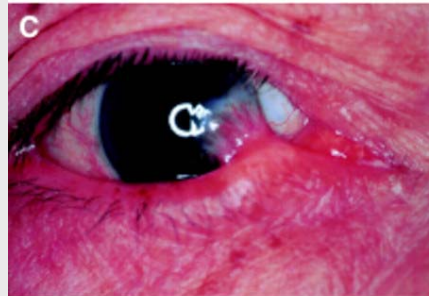
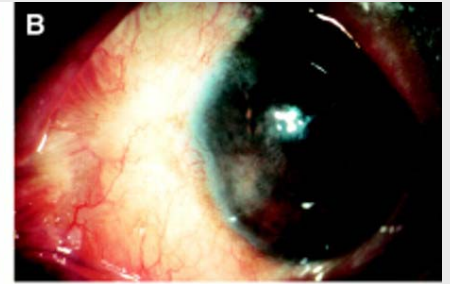
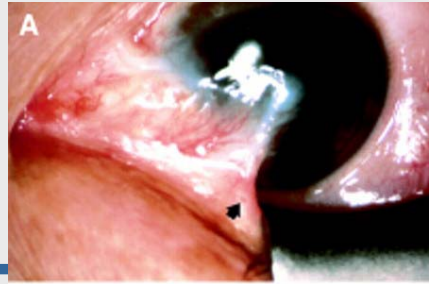Auto trapianto congiuntivale a lembo libero



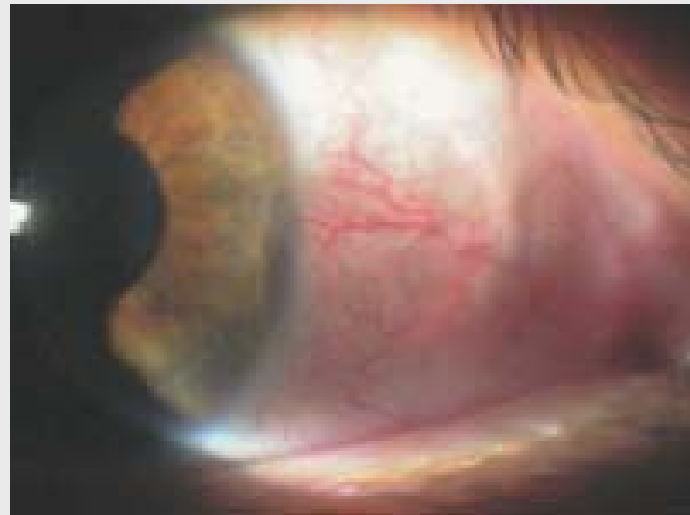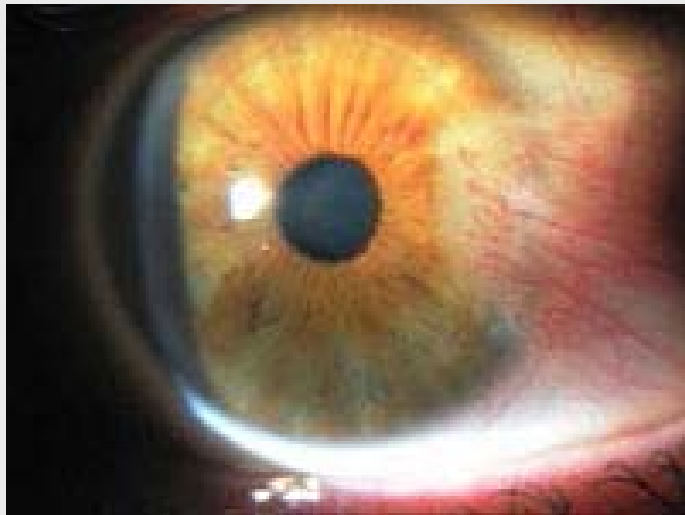




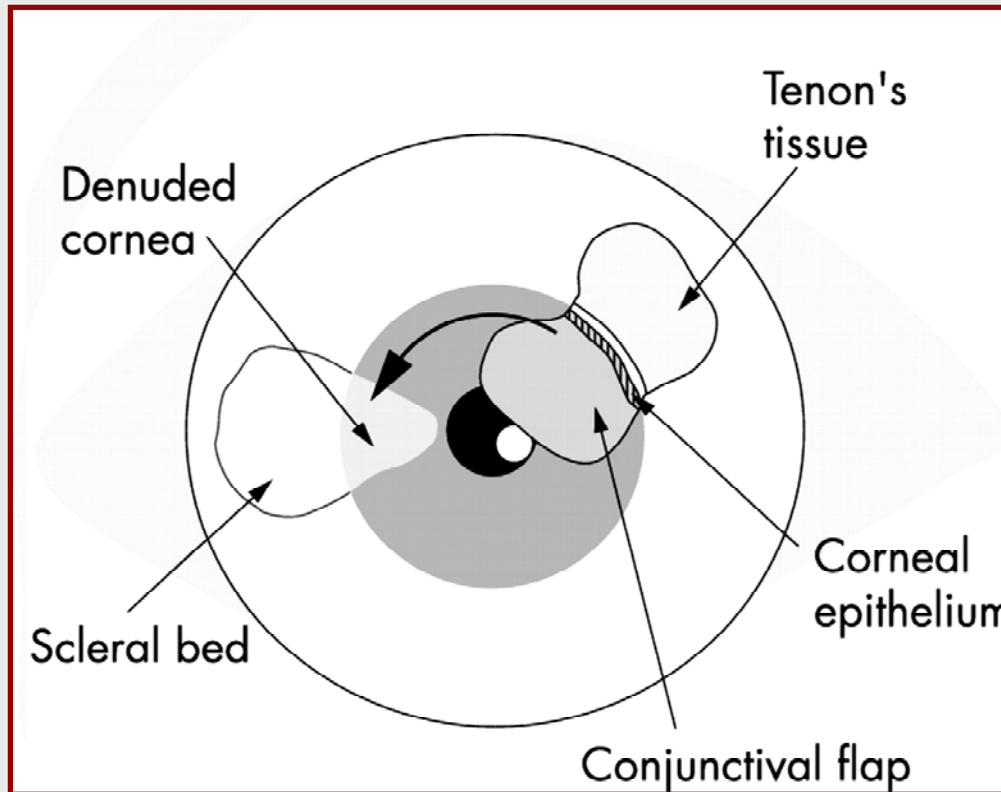
Auto trapianto congiuntivale a lembo libero



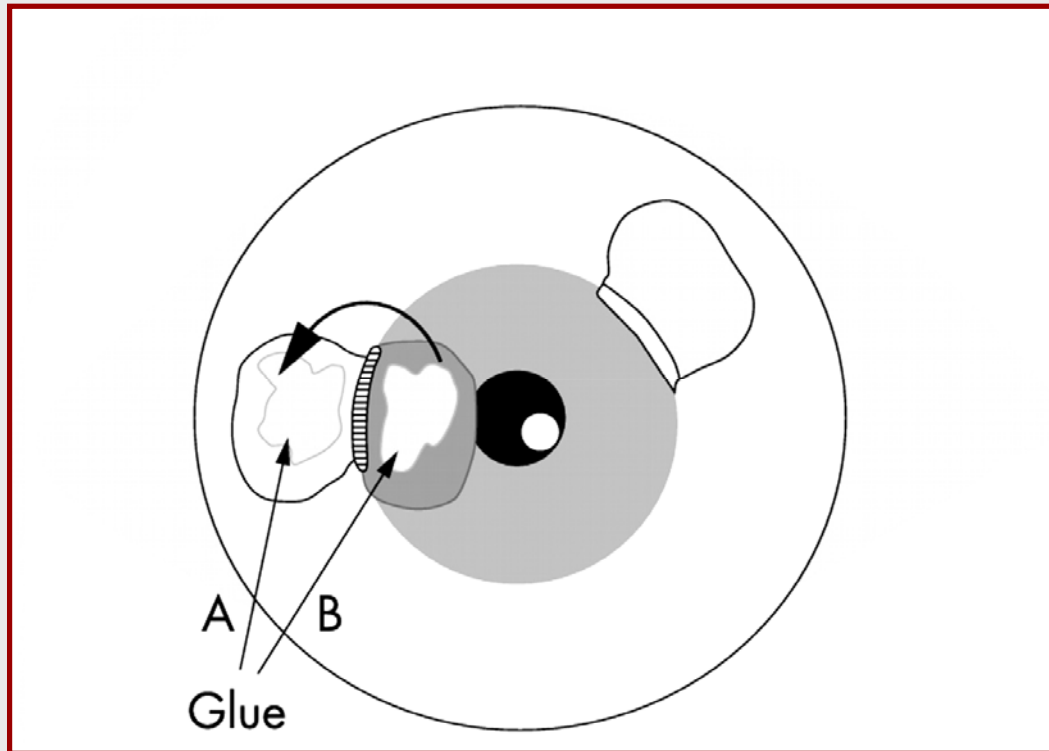
Trapianto Limbo - Congiuntivale



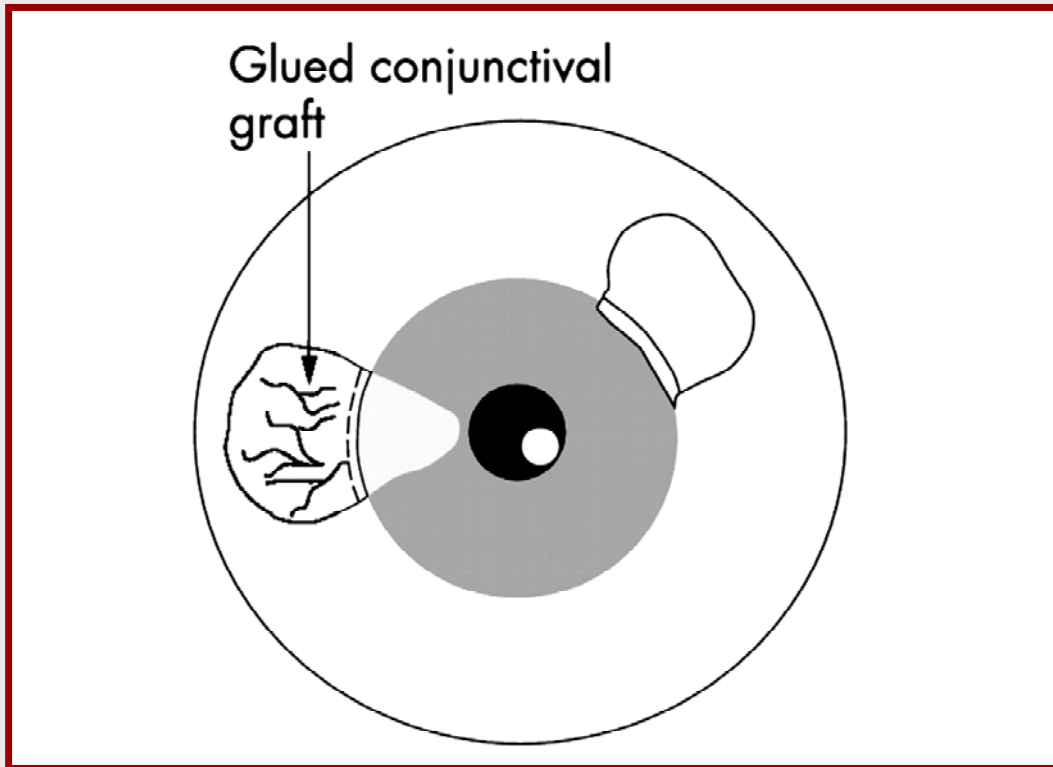
**Pterygium is excised.
The conjunctival transplant is prepared
lying upside down on the cornea.**



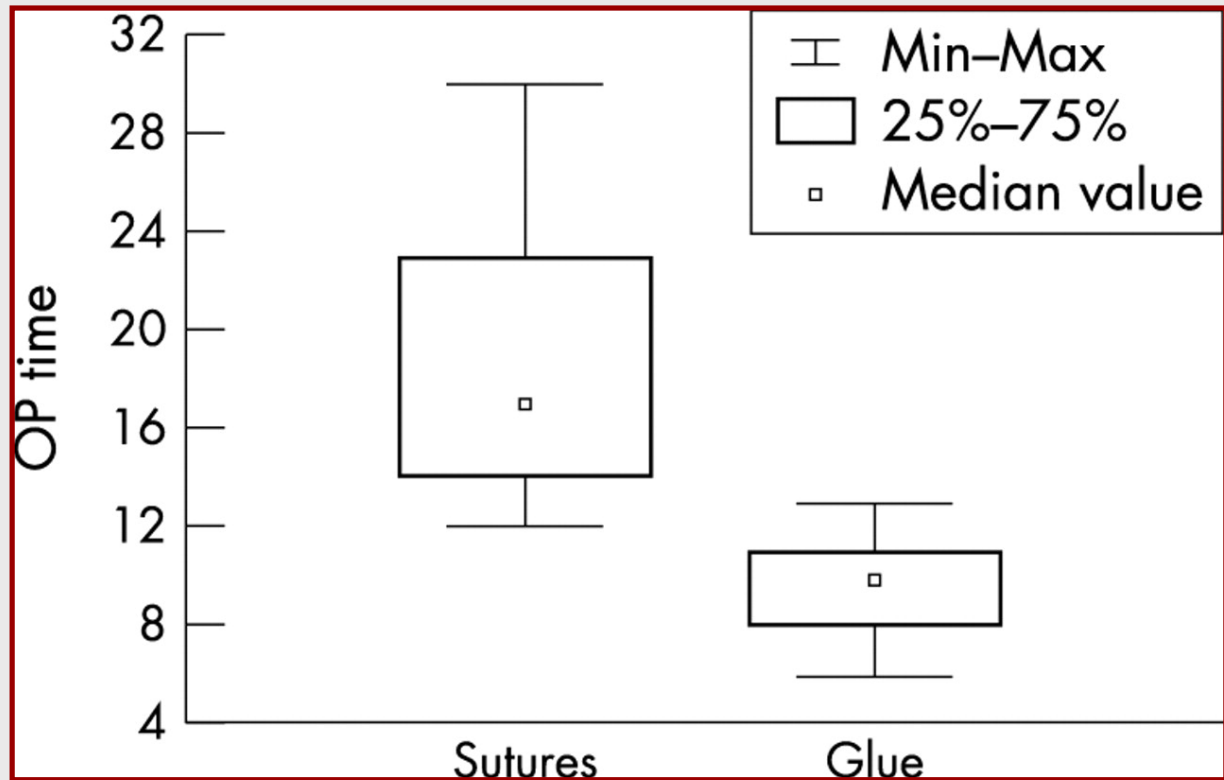
The conjunctival graft is slid nasally with the limbal edge facing towards the limbus. One drop of the thrombin solution (A) and one drop of the protein solution (B) are placed.



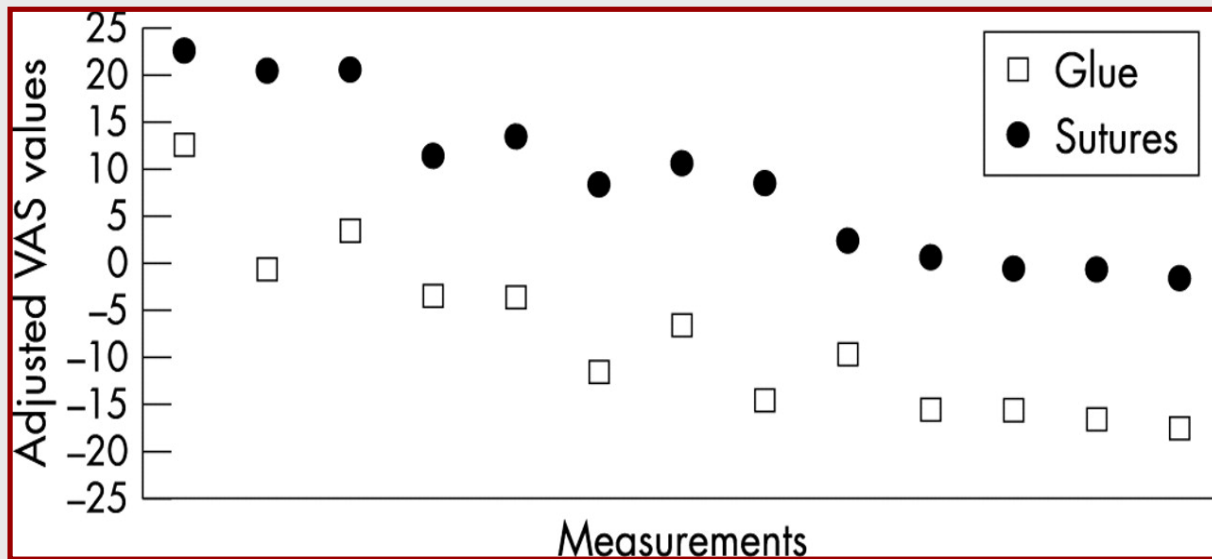
The graft is flipped over and glued.

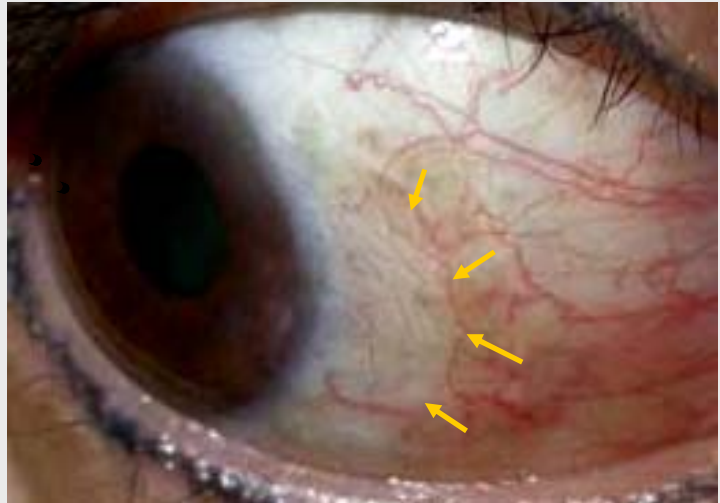
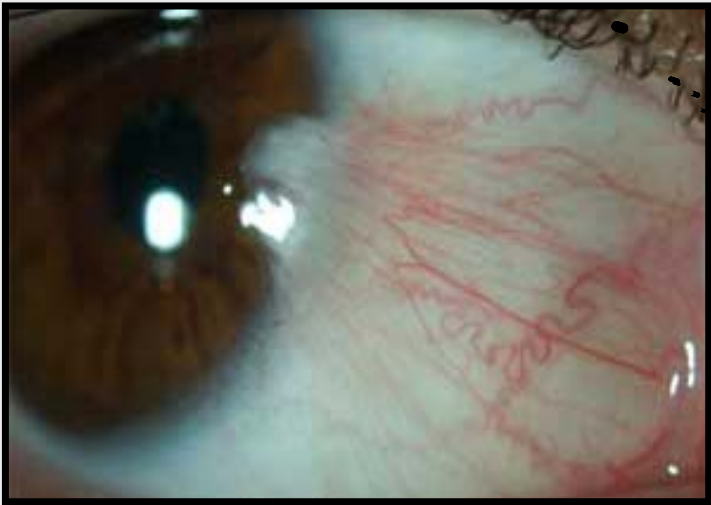


Box plot of surgery times in minutes. Medians, quartiles, minimum, and maximum values for each group are shown. The difference is significant, $p < 0.001$ (Mann-Whitney).



Medians of the adjusted postoperative VAS values. Glue and suture group monitored twice daily. At each point of time $p < 0.05$ (Mann-Whitney U test).

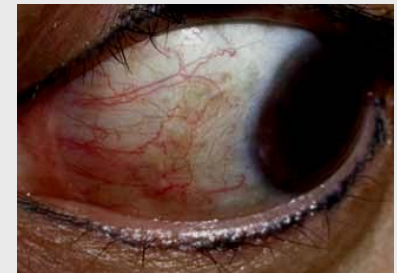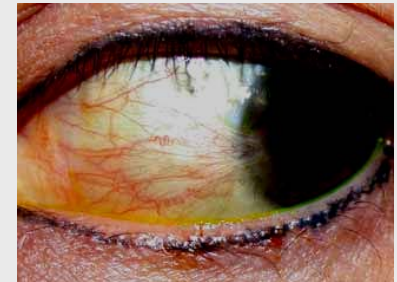




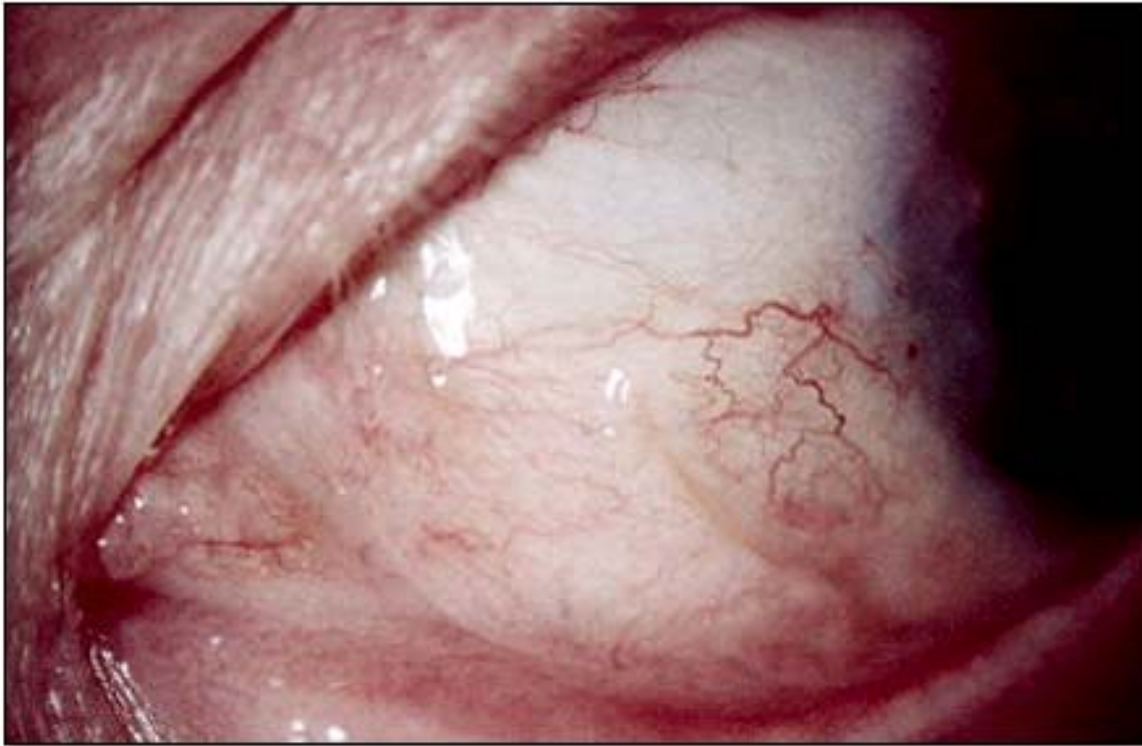
The cut-and-paste method for primary pterygium surgery: long-term follow-up

Koranyi, G.Seregard, S.Kopp, E. D. Acta Ophthalmol Scand 2005, 83: 298-301

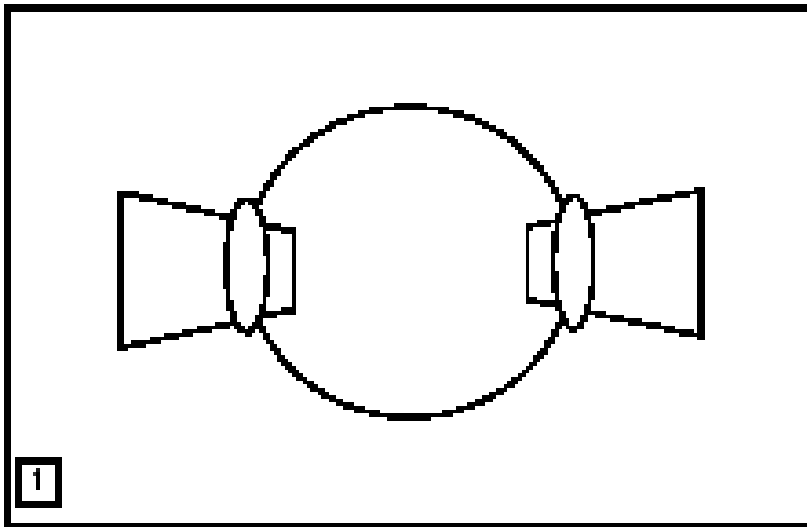
Intervento	Recidive	Reinterventi
Adesivo di fibrina	5,3	1,2
sutura	12,3	3,3



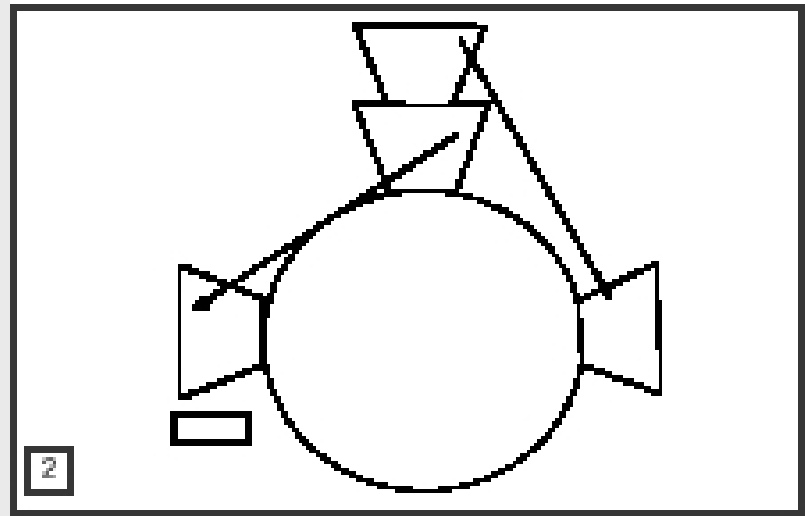
Uso dei collanti di fibrina nella chirurgia dello pterigio



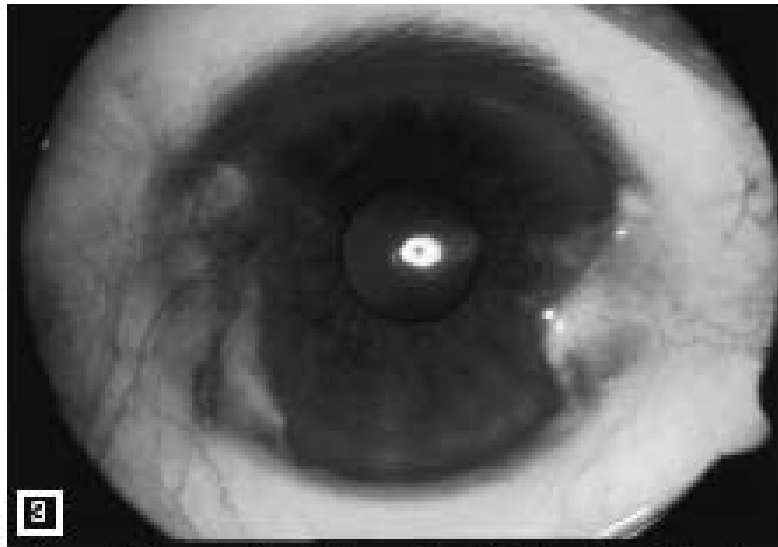
Pterygium graft secured with Tisseel. Photo taken 2 weeks after surgery.



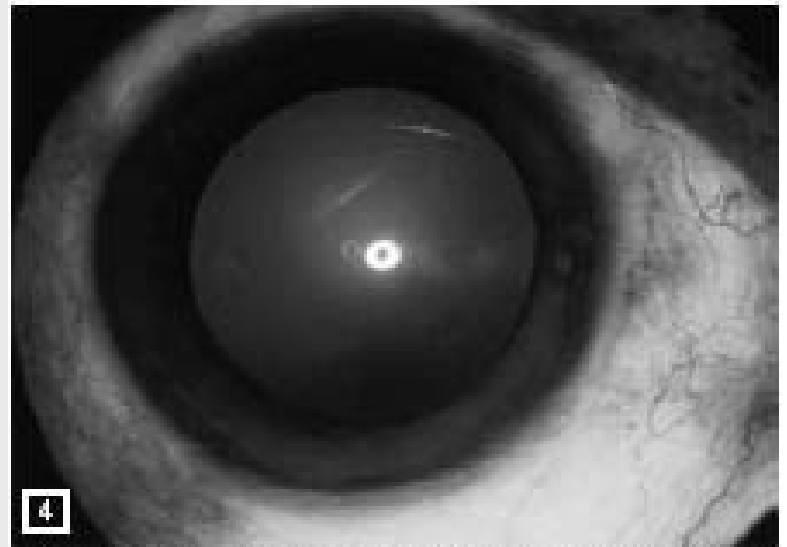
1
Figure 1. Conjunctival incisions on nasal and temporal side superior conjunctiva graft



2
; Figure 2. Dimensions of the bare scleral bed marked on superior conjunctiva



3
Figure 3. Preoperative photograph of double-head pterygium; month after surgery

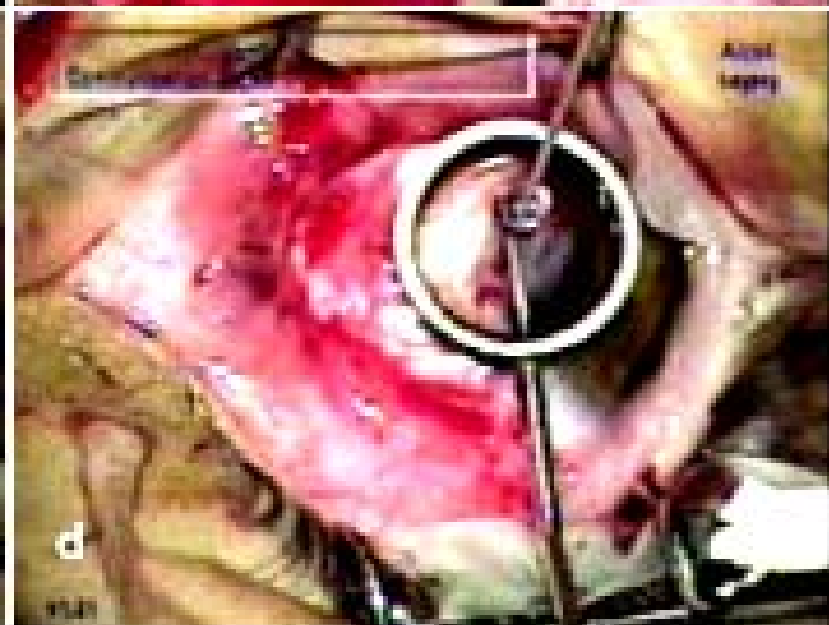
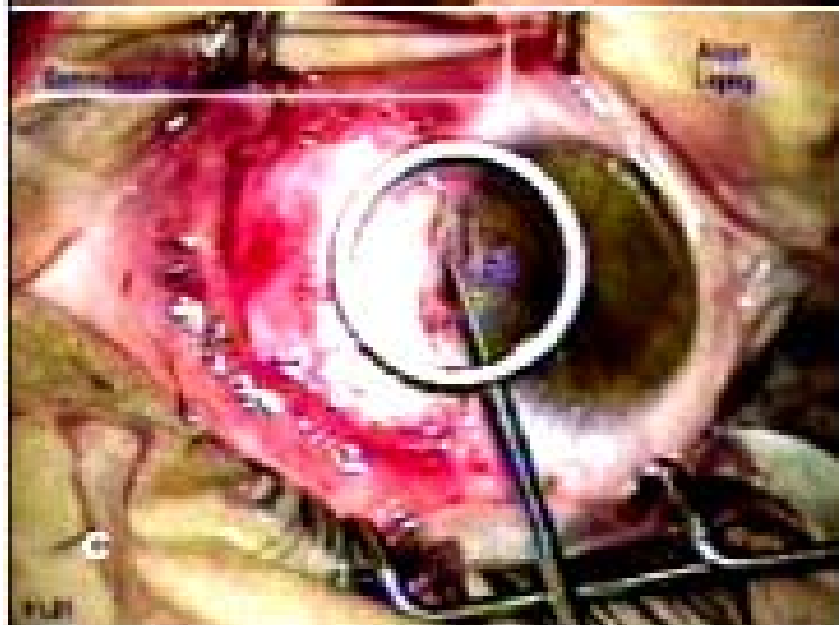
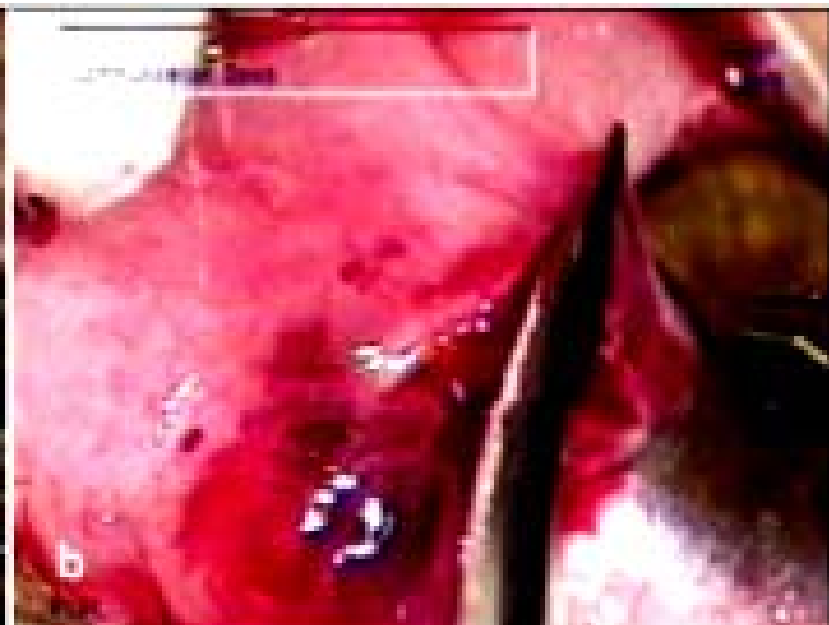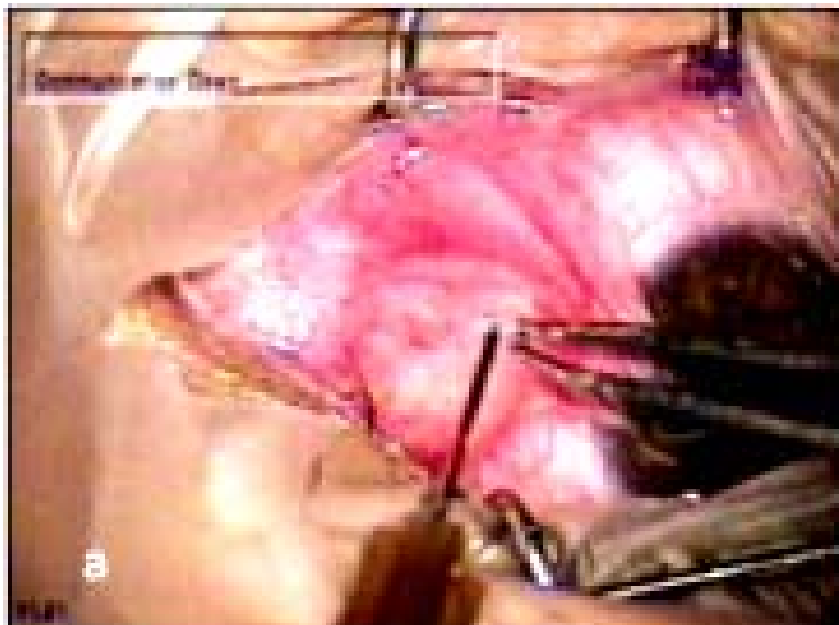


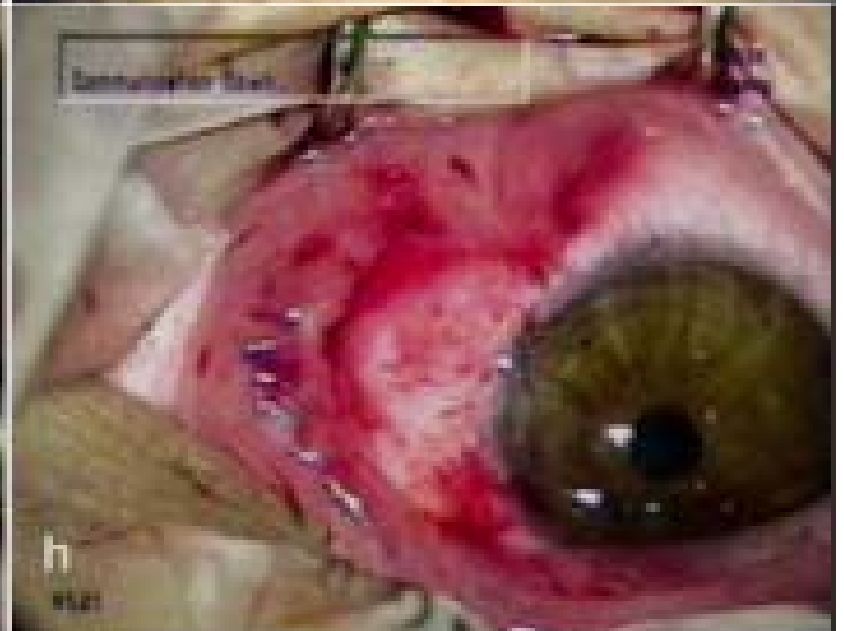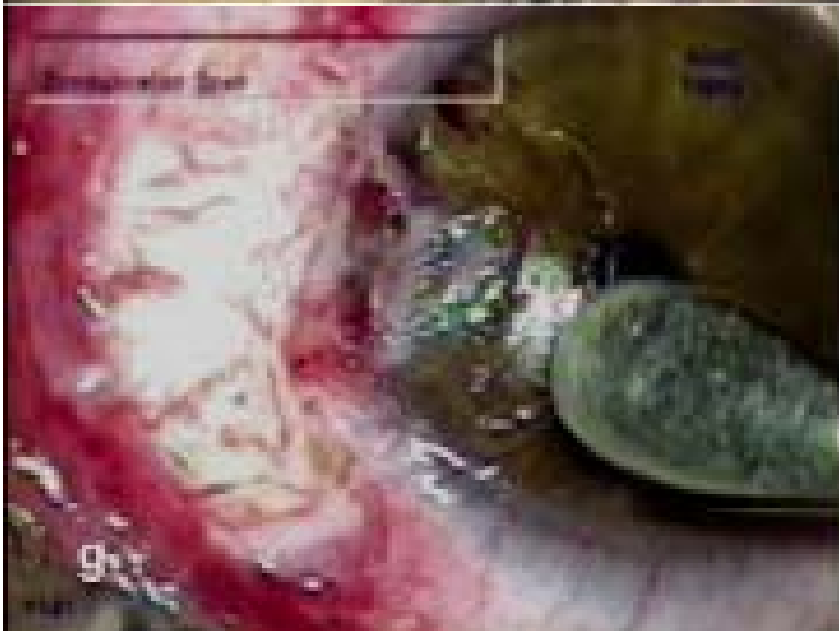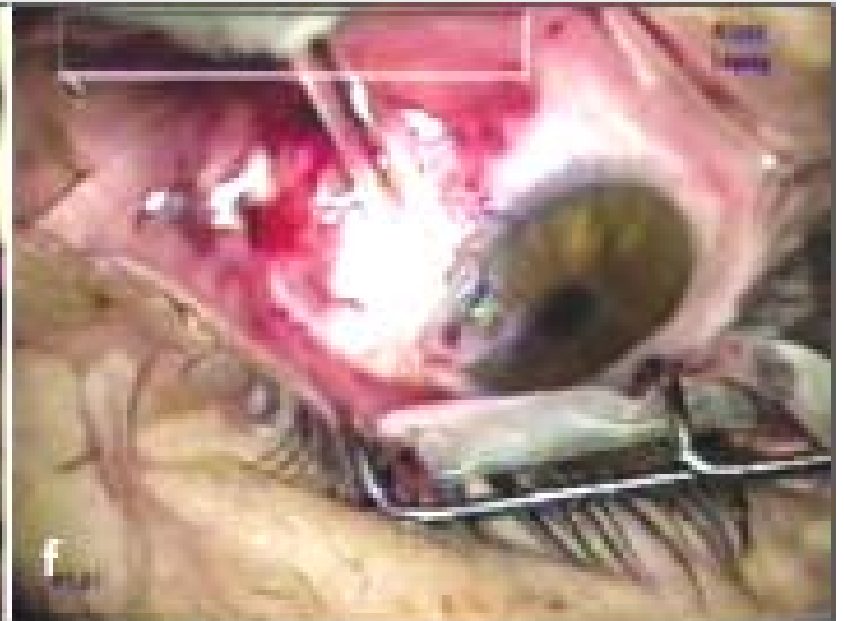
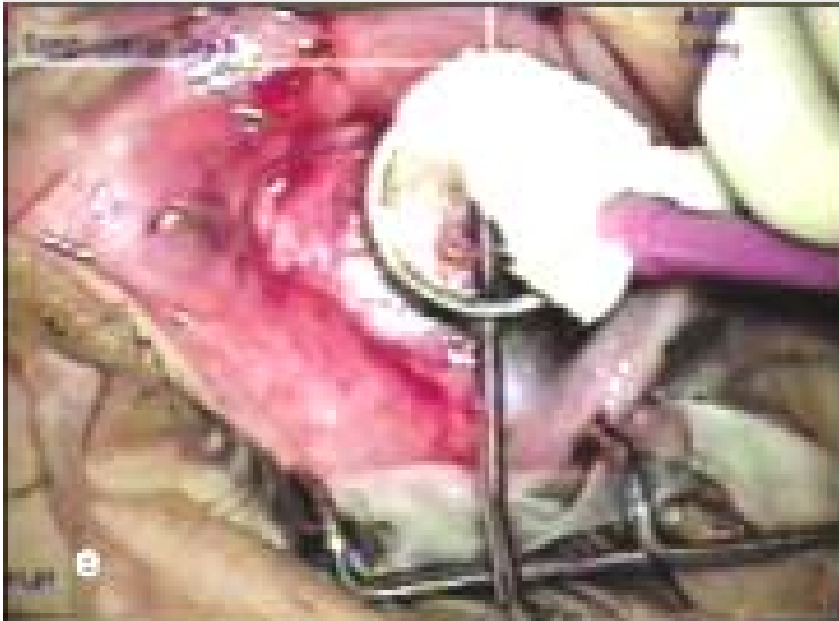
4
Figure 4. Postoperative photograph of the same eye one month after surgery

Management of primary pterygia using free conjunctival and limbal-conjunctival autografts without antimetabolites

Mejia, L. F. Sanchez, J. G. Escobar, H. Cornea, 2005, 24: 972-5

- 111 eyes of 90 patients underwent pterygium resection; a free conjunctival autograft was used in 88 surgeries and a free limbal-conjunctival autograft in 24;
- RESULTS:
 - Mean follow-up was 9 months (range, 3-12).
 - There were 2 recurrences (1.8%), both observed in the third postoperative month.
- CONCLUSIONS: the incidence of recurrence after primary pterygium surgery is very low, making the use of antimetabolites unnecessary.





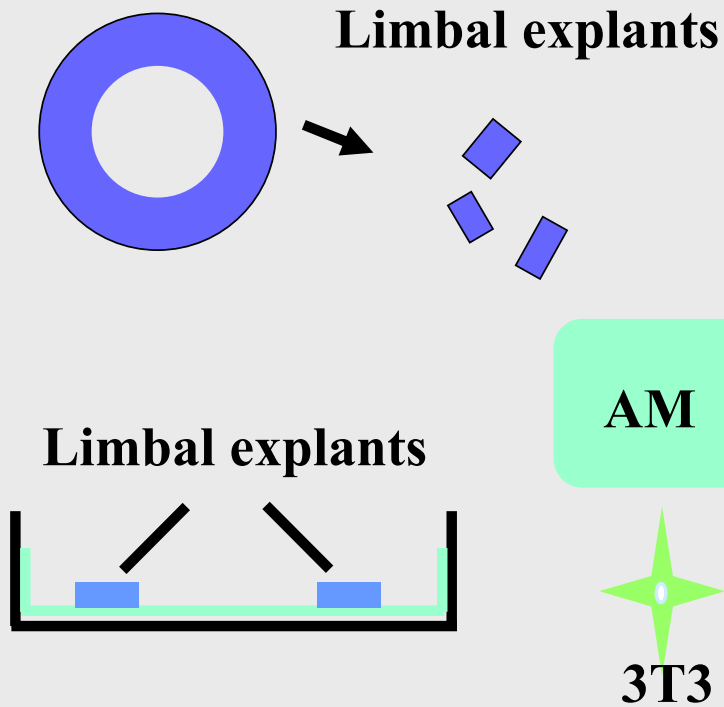
Autologous cultivated conjunctival transplantation for pterygium surgery.

Ang, L. P.Tan, D. T.Cajucom-Uy, H.Beuerman, R. W. Am J Ophthalmol. 2005, 139, 4:611-19

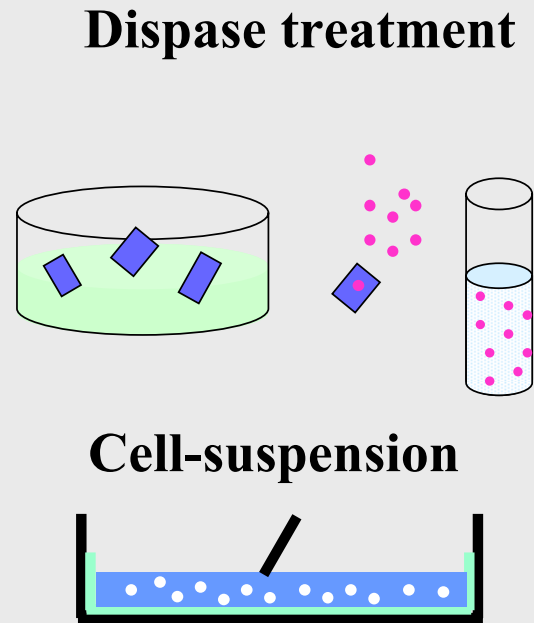
- Excision of the pterygium was followed by reconstruction using a serum-free derived autologous cultivated conjunctival equivalent in 22 patients (group A) and conventional denuded amniotic membrane transplantation in 18 patients (group B).
- In group A patients, conjunctival epithelial equivalents were constructed by the ex vivo expansion of conjunctival epithelial cells on human amniotic membranes (HAM).
- The main outcome measures were
 - conjunctival epithelialization,
 - recurrence,
 - survival analysis, and
 - incidence of complications.
- **RESULTS:** The mean follow-up was 14.1 +/- 3.9 months (range, 12 to 25 months).
 - Complete epithelialization was achieved within five days after surgery in group A patients compared with approximately three weeks for group B patients.
 - The proportion of patients that had true recurrences was 22.7% in group A and 25.0% in group B. The mean time to recurrence was 4.8 +/- 1.6 months in group A and 5.0 +/- 2.9 months in group B.
 - No ocular complications were noted in group A, while one eye (6.0%) in group B developed scleral necrosis associated with a persistent epithelial defect.
- **CONCLUSIONS:** Transplantation of an autologous cultivated conjunctival epithelial sheet facilitated early postoperative epithelialization and recovery, and may aid in preventing serious complications associated with simple denuded HAM transplantation, such as scleral necrosis and secondary infection. This may provide a novel method for conjunctival epithelial replacement in the treatment of ocular surface disorders.

Human Corneal Stem Cell Culture on AM

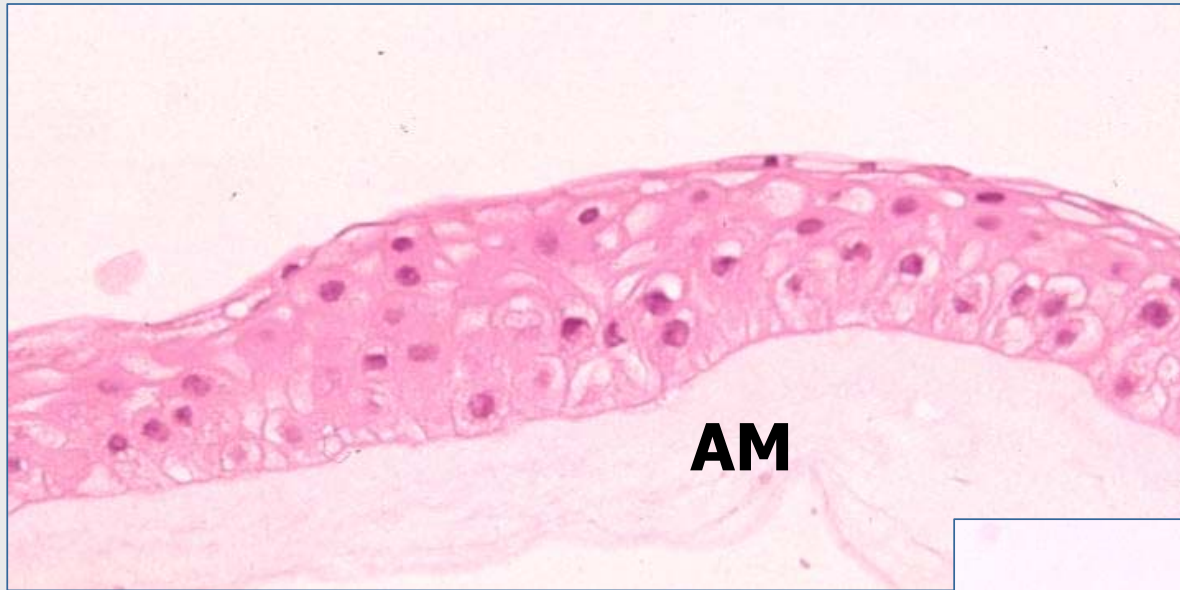Explant



Cell-suspension

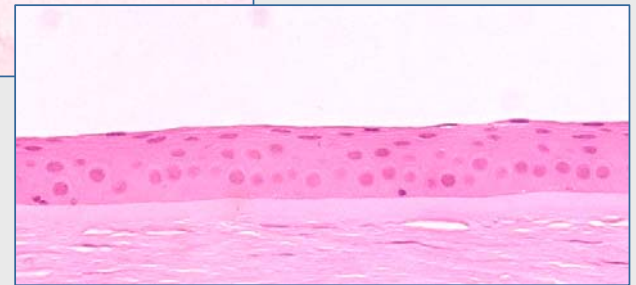


Cultivated Corneal Epithelium on AM



AM

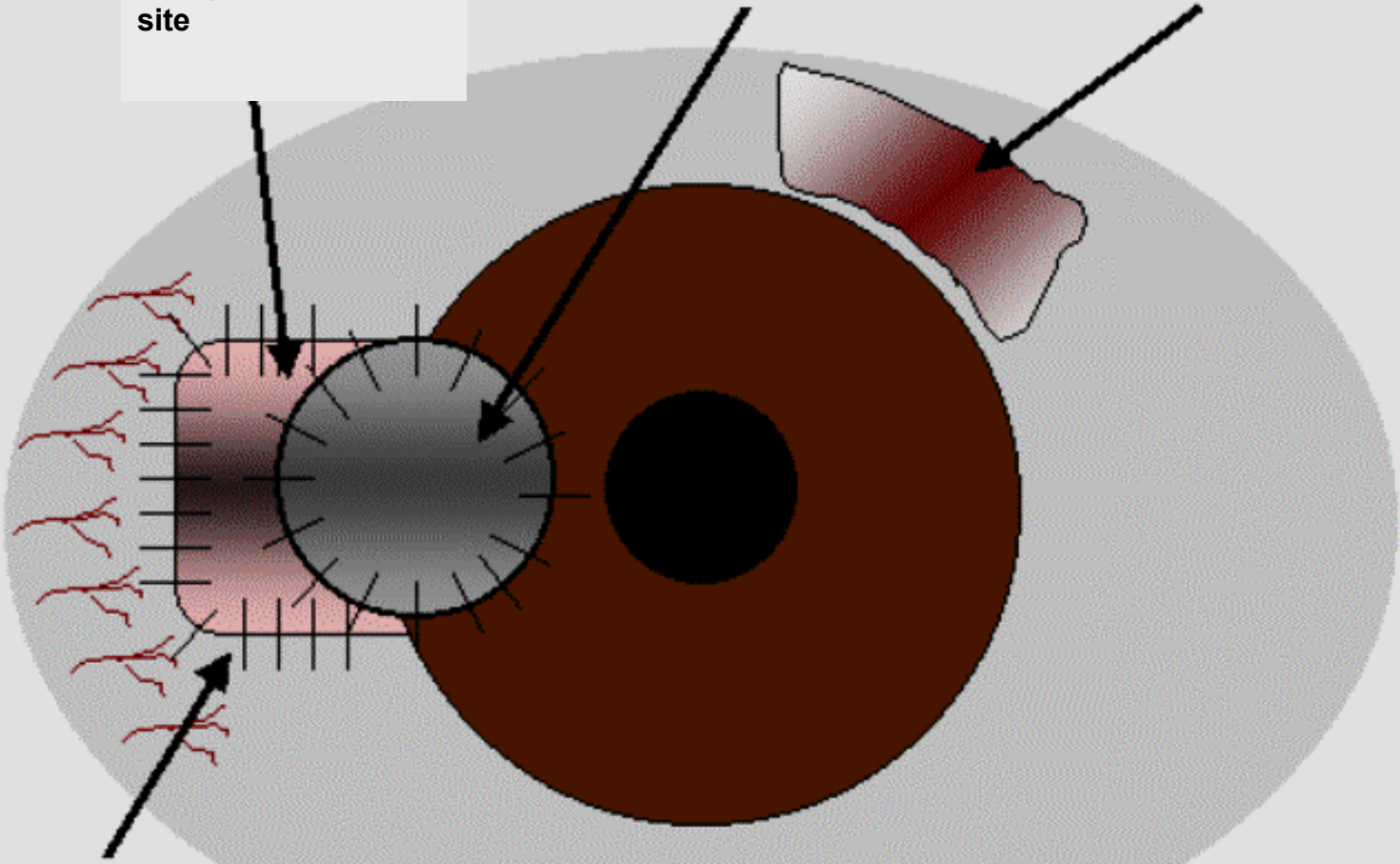
in vivo corneal
epithelium →



Conjunctival autograft recipient site

Lamellar Corneal Graft

Conjunctival autograft donor site



Simple interrupted Nylon 10-0 sutures

Lamellar corneal graft in the treatment of pterygium. A 10-year retrospective study of the recurrence and changes of astigmatism

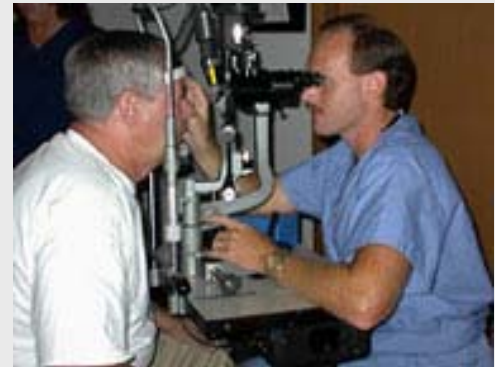Simona, F. Tabatabay, C. A. Leuenberger, P. M. J Fr Ophtalmol 1988 11 759-63

- 57 eyes with a pterygium
- corneoscleral lamellar excision of pterygium followed by a corneal lamellar keratoplasty.
 - mean follow-up of 37 months,
 - recurrence in 2 eyes (3.5%).
 - corneal astigmatism measured with a Javal keratometer showed a modification in 54 eyes (95%).
 - Visual acuity
 - improved in 4 (7%) eyes,
 - was unchanged in 29 (51%) and
 - **deteriorated** in 23 (40%) eyes.
- The benefits of the low recurrence rate after this surgical procedure are to be weighed against the risk of modification of the corneal astigmatism and the possible modification of the visual acuity

Photodynamic therapy for wound-healing modulation in pterygium surgery. A clinical pilot study

Hueber, A., Grisanti, S., Graefes Arch Clin Exp Ophthalmol 2005, 243, 9: 942-6

- The applied PDT technique seems to be a safe procedure but is associated with a high rate of recurrence.
- PDT treatment procedure, should not be considered for pterygium treatment.



Chirurgia dello Pterigio

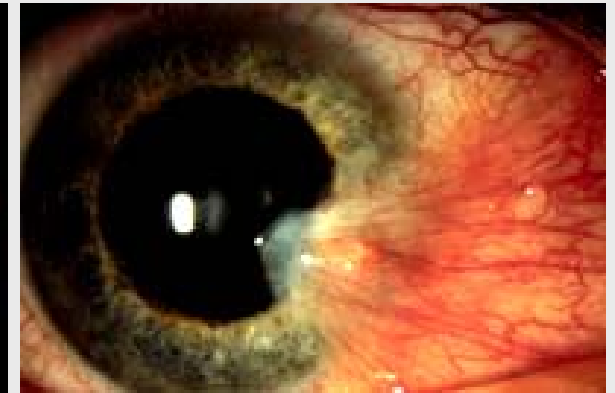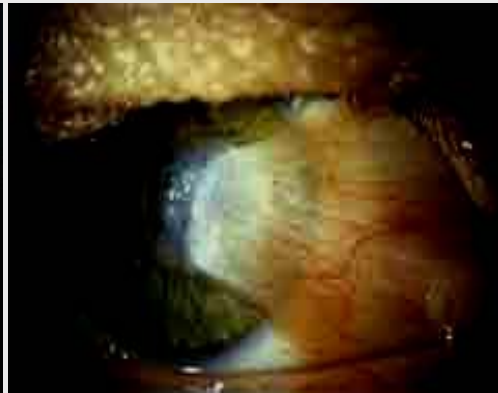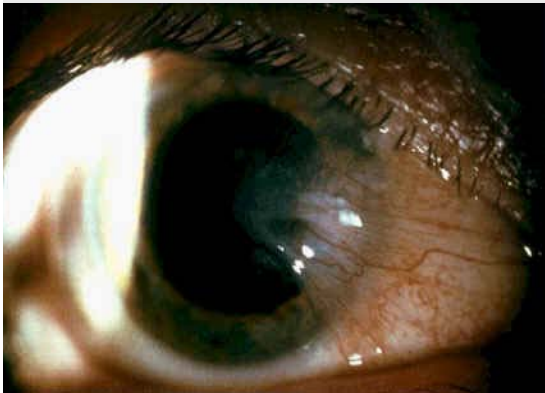Intervento	Recidive precoci (3 mesi)	Recidive dopo 1 anno	Recidive post 2° int
Sclera nuda	20 %	81 %	90 %
Sclera nuda + Radiazione	11 %	43 %	
Sclera nuda +Eccimeri+MMC	2,9 %		
M.Amniotica su Sclera nuda	11 %	67 %	
Plastica congiuntivale	12 %	27 %	45 %
Trapianto congiuntivale (congiuntivo limbare) + MMC	1 %	13 %	2 %
+ M.Amniotica + MMC	1,8 %	5,2 % (Colla)	
		0.3 %	

Avisar R, Weinberger D. Pterygium surgery with mitomycin C: how much sclera should be left bare? *Cornea*. 2003 Nov;22(8):721-5. Hirst LW. The treatment of pterygium. *Surv Ophthalmol*. 2003 Mar-Apr;48(2):145-80. Review. Kal HB, Mourits MP, Wyrdean HK. Prevention of pterygium recurrence by postoperative single-dose beta-irradiation: a prospective randomized clinical double-blind trial. *Int J Radiat Oncol Biol Phys*. 2004 Jul 15;59(4):1138-47. Dadeya S. Conjunctival rotation autograft. *Ophthalmologica*. 2003 Nov-Dec;217(6):454. Fernandes M, Sangwan VS, Bansal AK. Outcome of pterygium surgery: analysis over 14 years. *Eye*. 2005 Nov;19(11):1182-90. Ma DH, See LC, Hwang YS, Wang SF. Comparison of amniotic membrane graft alone or combined with intraoperative mitomycin C to prevent recurrence after excision of recurrent pterygia. *Cornea*. 2005 Mar;24(2):141-50. Hueber A, Grisanti S, Diestelhorst M. Photodynamic therapy for wound-healing modulation in pterygium surgery. A clinical pilot study. *Graefes Arch Clin Exp Ophthalmol*. 2005 Sep;243(9):942-6. Mejia LF, Sanchez JG, Escobar H. Management of primary pterygia using free conjunctival and limbal-conjunctival autografts without antimetabolites. *Cornea*. 2005 Nov;24(8):972-5. Miyai T, Hara R, Nejima R, Miyata K, Yonemura T, Amano S. Limbal allograft, amniotic membrane transplantation, and intraoperative mitomycin C for recurrent pterygium. *Ophthalmology*. 2005 Jul;112(7):1263-7.

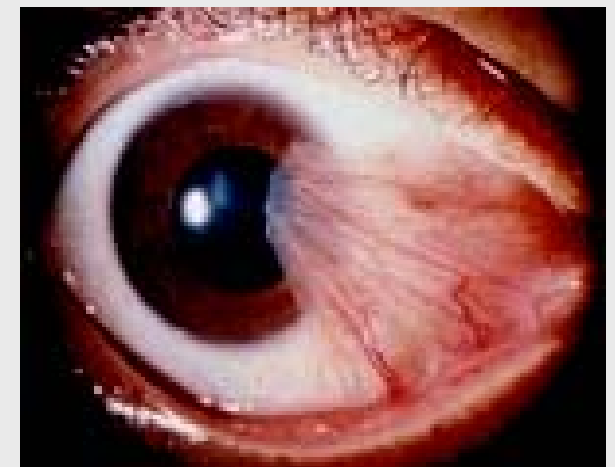Chirurgia dello Pterigio: analisi dei risultati della letteratura:

- Non esiste una classificazione adeguata, accettata e utilizzata
 - Nella chirurgia non si sa di quale tipo di pterigio si sta parlando
 - Spesso non sono definite le caratteristiche del corpo e dei vasi, ma (se va bene) solo l'estensione
 - Non si sa il rischio relativo di recidiva dello pterigio di partenza (attivo? non attivo?)
- Dati e informazioni poco trasferibili

Classificazione dello Pterigio

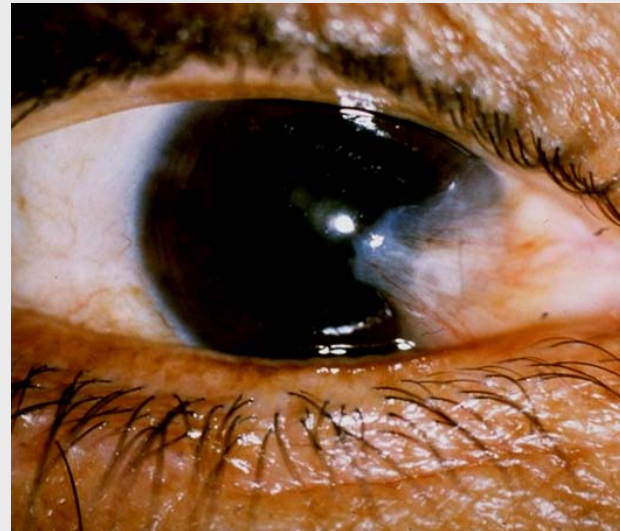


Antonio Mastromarino
Maurizio Rolando



Parametri Classificazione

- **Invasione Corneale**
- **Invasione Limbare**
- **Rilevo**
- **Congestione Vascolare**
- **Trazione**



Parametri di Classificazione

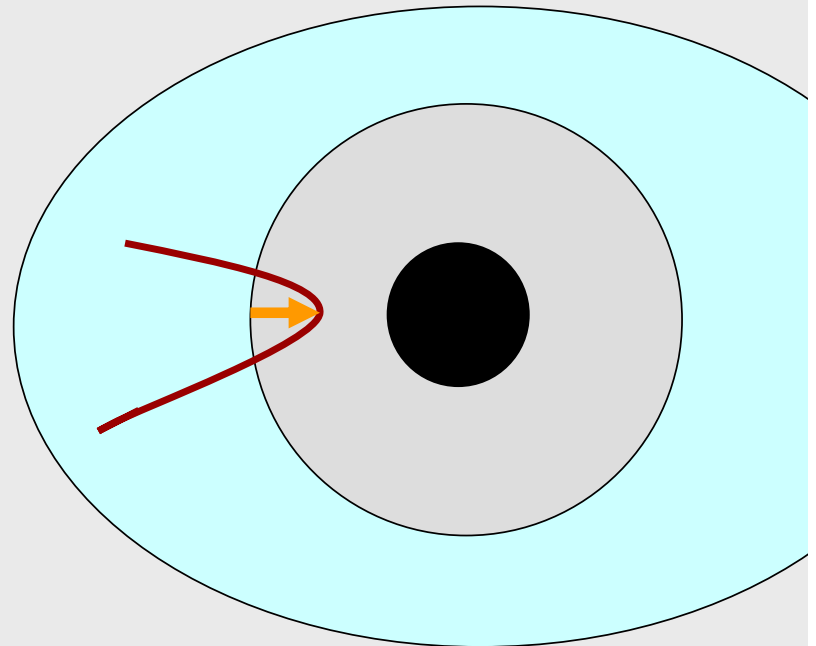
■ Invasione Corneale:

1p <1mm

2p tra 1 e 3mm

3p > 3mm

4p invasione asse
visivo



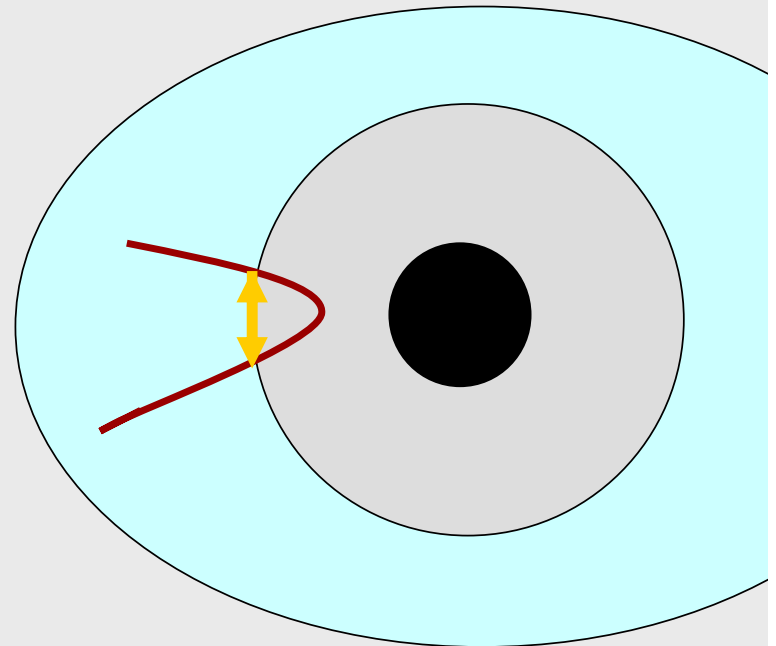
Parametri Classificazione

- **Invasione Limbare:**

1p < 2 mm

2p tra 2 e 4 mm

3p > 4 mm



Parametri Classificazione

- **Congestione Vascolare:**

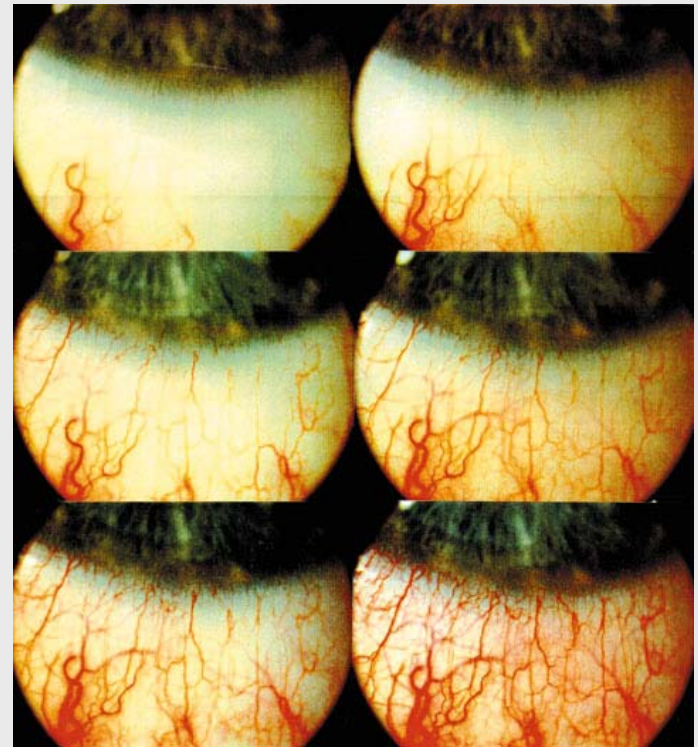
1p 1° e 2° grado

2p 3° e 4° grado

3p 5° grado

4p 6° grado

N.B. Metodica classificativa per confronto (Mc Monnies)



Parametri Classificazione

- **Rilievo:**

- 1p aspetto piano, visibili vasi sclerali

- 2p lievemente rilevato, vasi sclerali mal visibili

- 3p rilevato, vasi sclerali non visibili

N.B.

Metodica classificativa per confronto

Parametri Classificazione

■ **Trazione:**

0 p: no trazione

1 p: spostamento plica semilunare
in posizione secondaria (abduz) di
sguardo

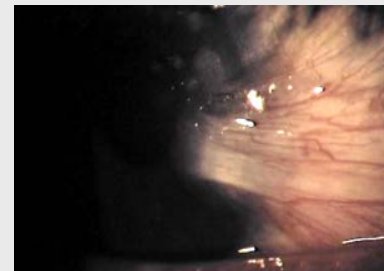
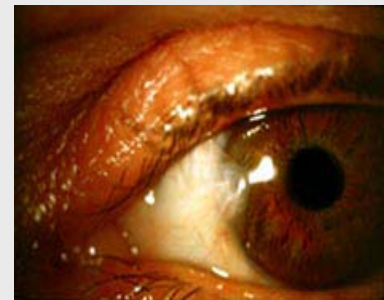
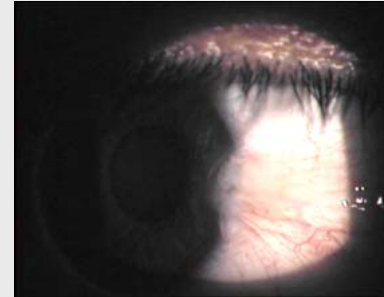
2 p: spostamento plica semilunare
in posizione primaria di sguardo

Invasione Corneale

■ A < 1 mm

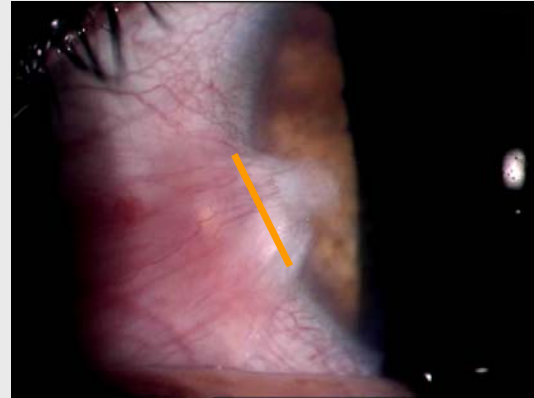
■ B $1 < x < 3$ mm

■ C > 3 mm

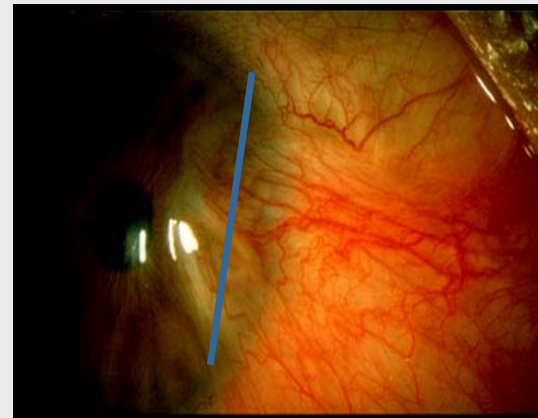


Invasione Limbare

■ $A < 2 \text{ mm}$

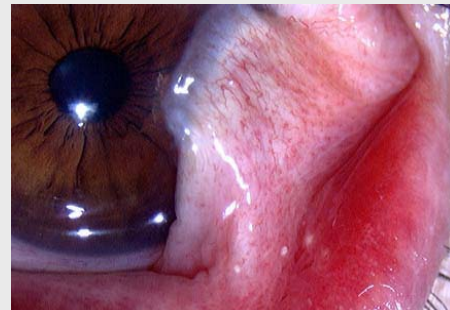
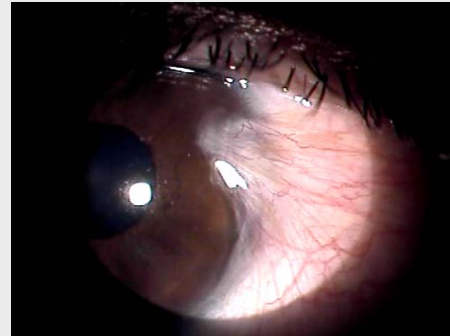
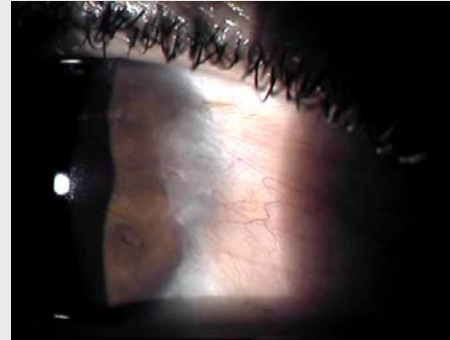


■ $B > 2 \text{ mm}$



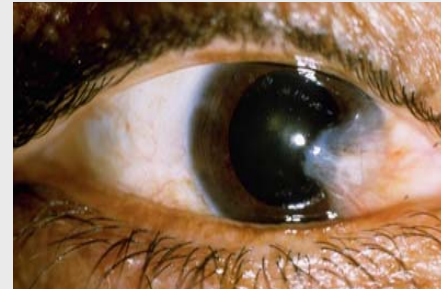Rilevo

- 1p: aspetto piano
- 2p: aspetto moderatamente rilevato
- 3p: aspetto fortemente rilevato

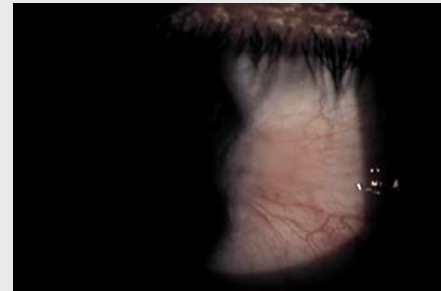

Congestione Vascolare

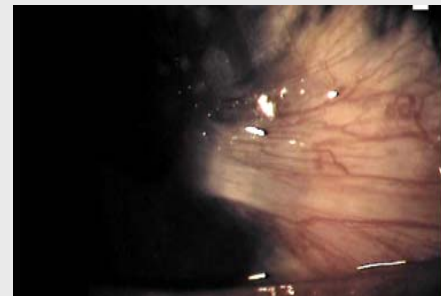■ 1p: 2° grado



■ 2p: 3° grado



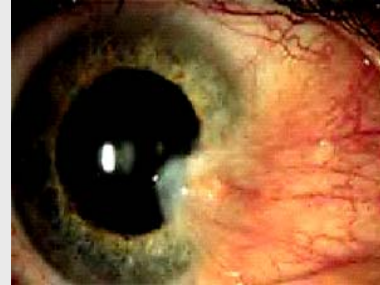■ 2p: 4° grado



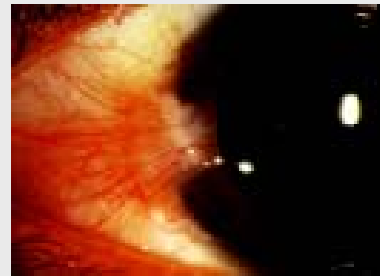
Mc Monnies

Congestione Vascolare

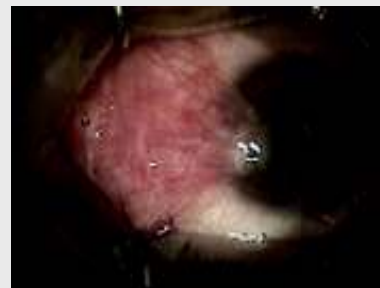■ 3p: 5° grado



■ 4p: 6° grado



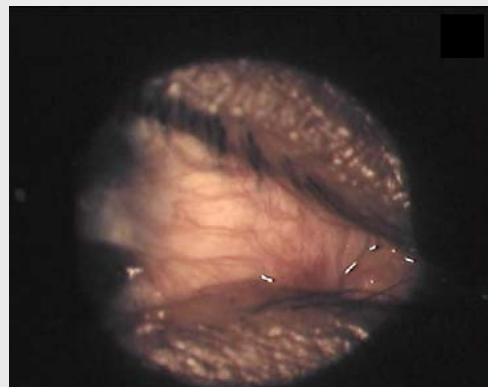
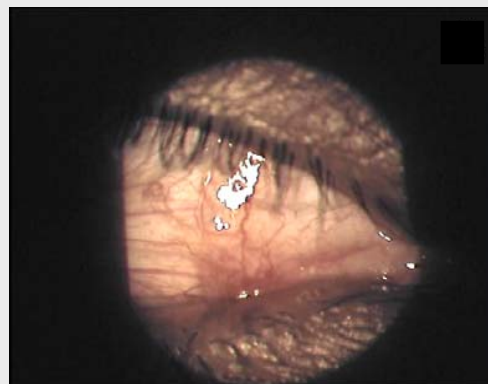■ 4p: 6° grado



Mc Monnies

Trazione

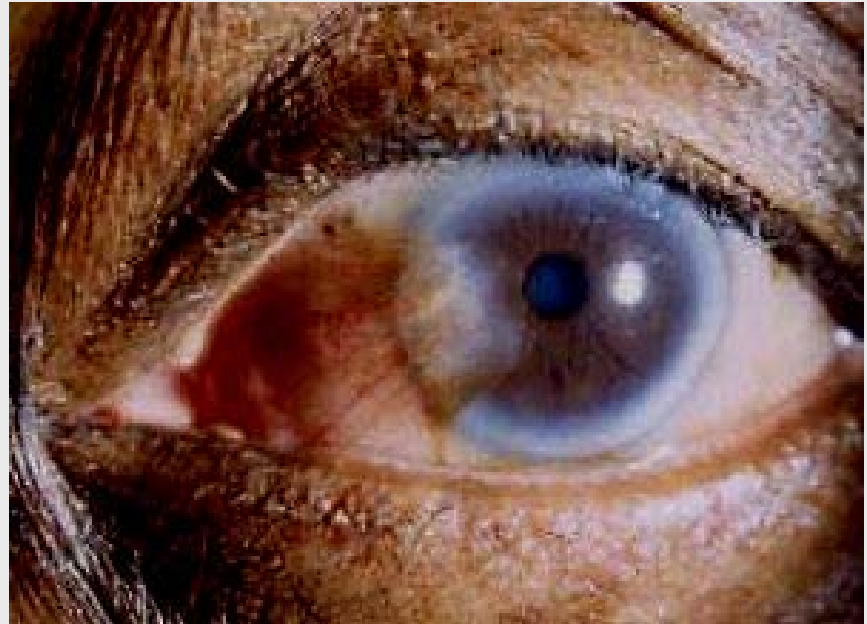- 0: no trazione
- 1: spostamento plica semilunare posizione 2°
- 2: spostamento plica semilunare posizione 1°



Stadiazione

- 1° stadio: 4 punti
- 2° stadio: tra 5 e 8 punti
- 3° stadio: tra 9 e 12 punti
- 4° stadio: tra 13 e 15 punti
- 5° stadio: 16 punti

Esempio



- $3IC+3IL+3CV+2R+2T = 13p \rightarrow 4^{\circ}$ stadio



Carsten Holler , mixed media, 1999